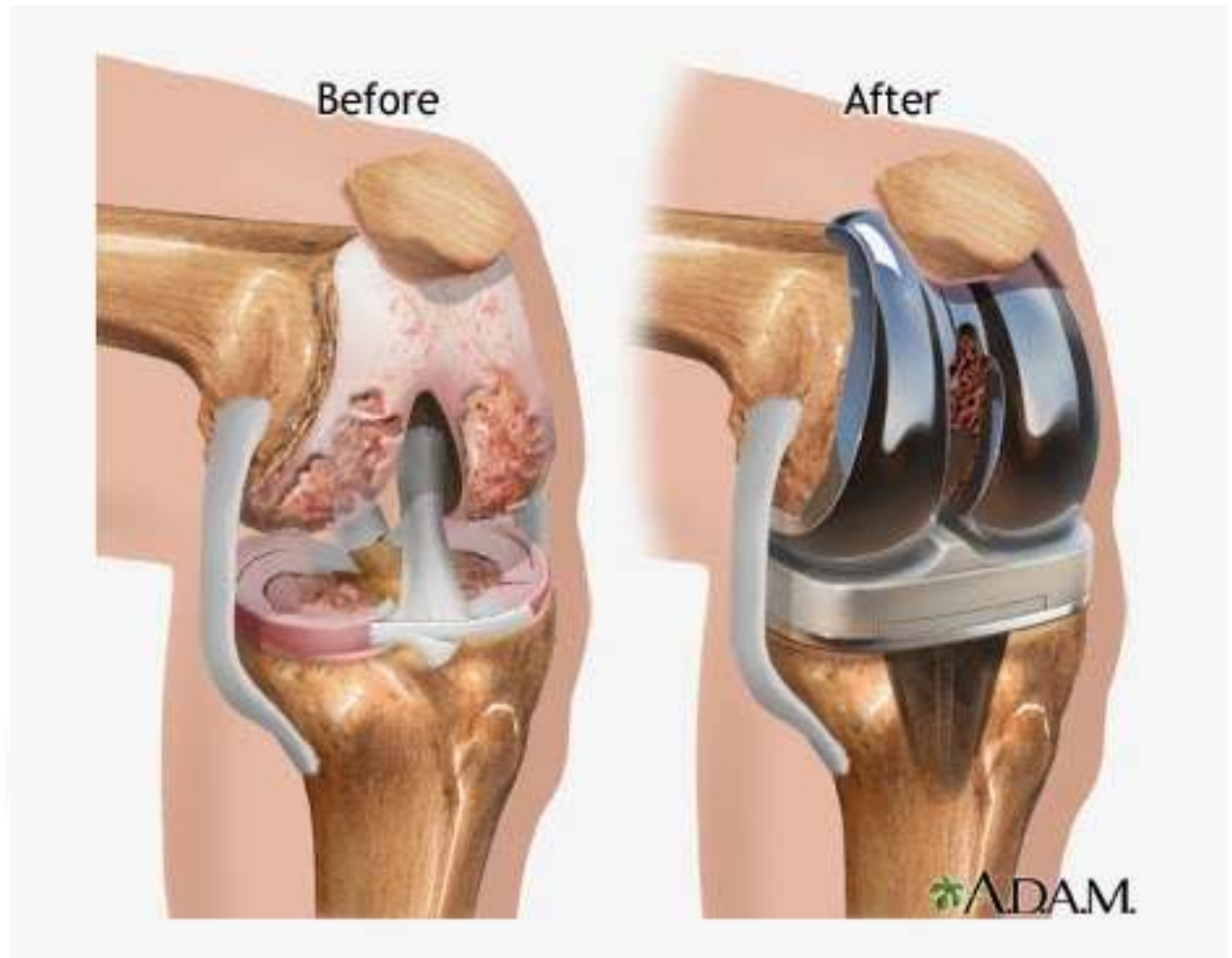
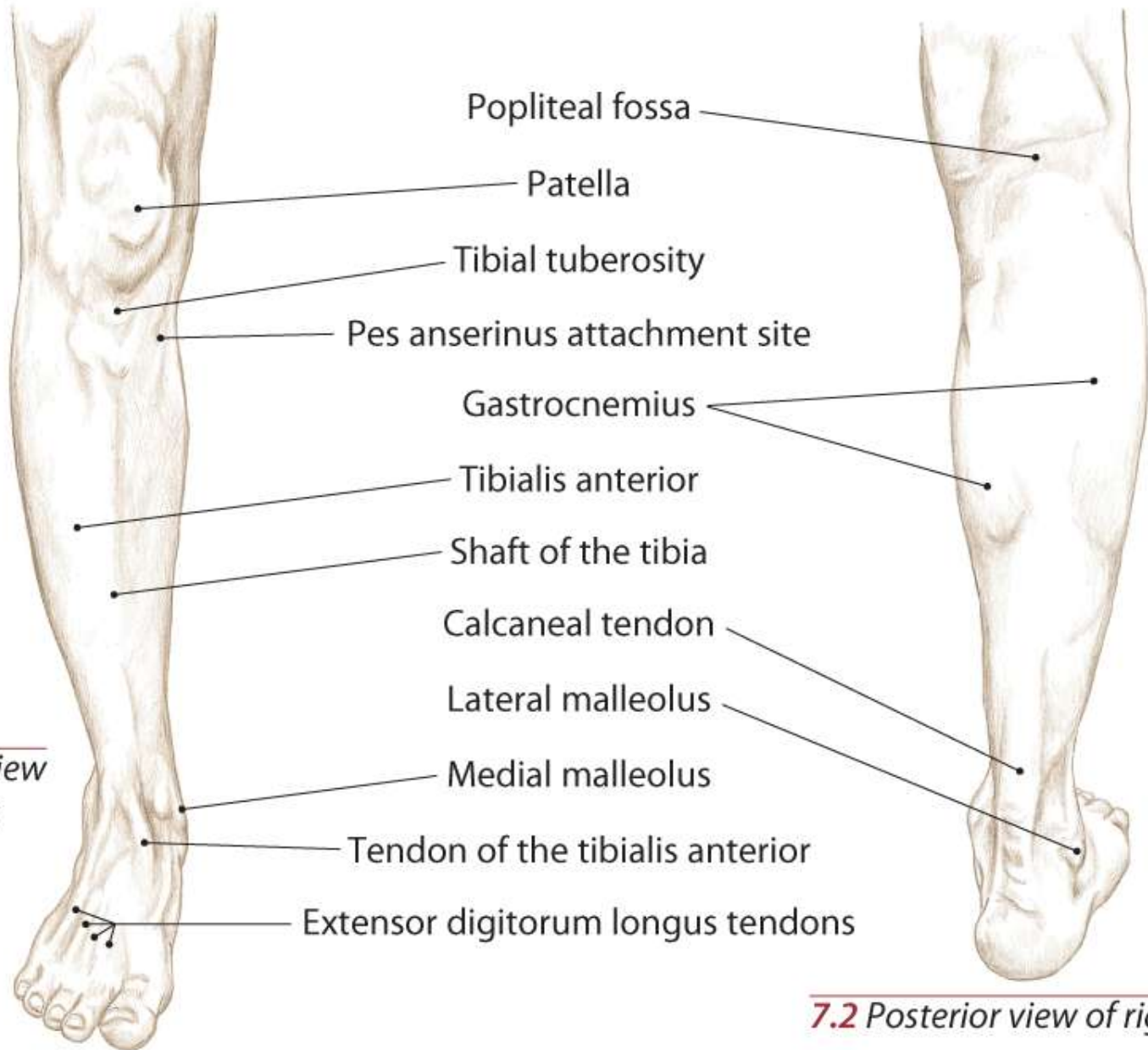


Knee Anatomy



Topographical Views

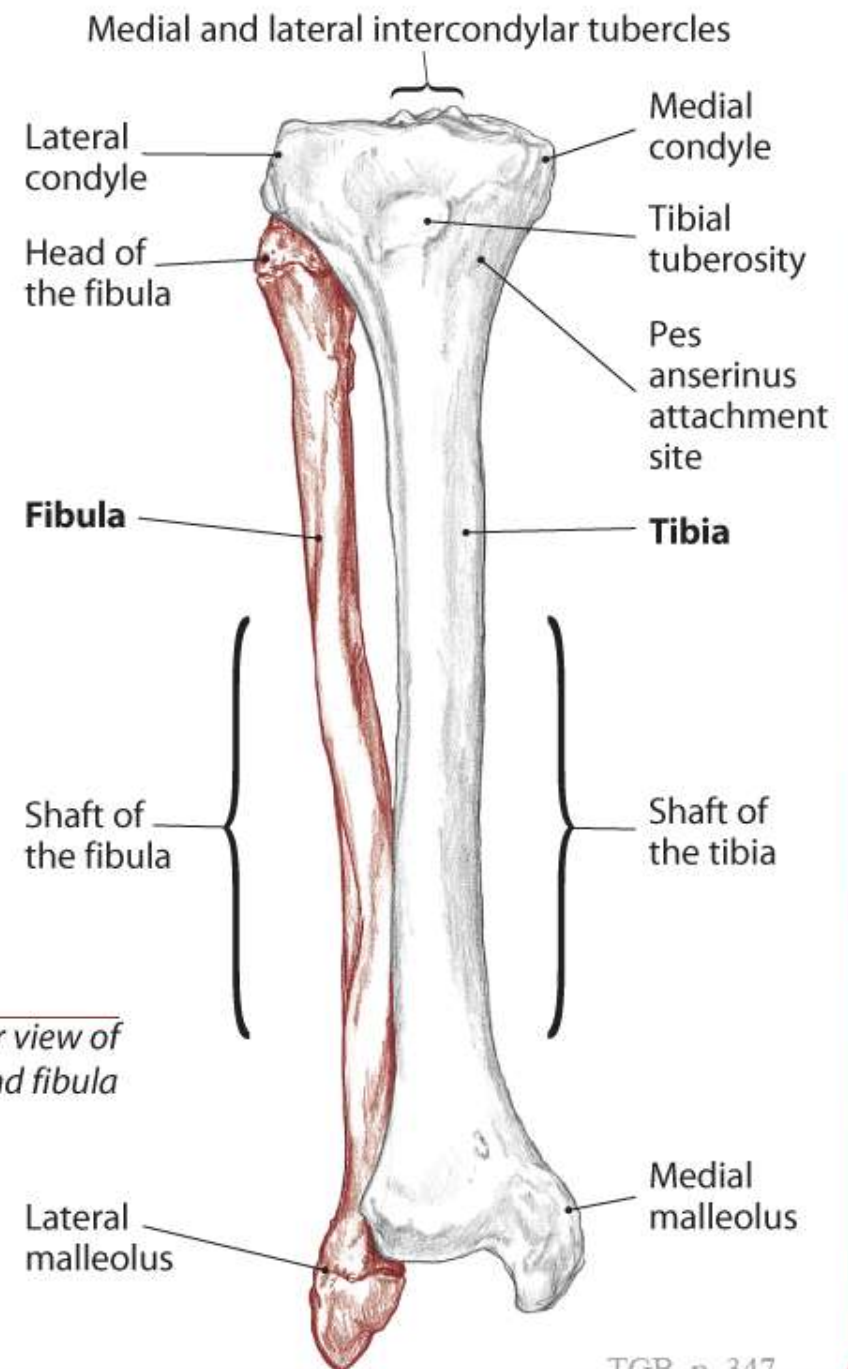
7.1 Anterior view of right leg



7.2 Posterior view of right leg

Tibia and Fibula

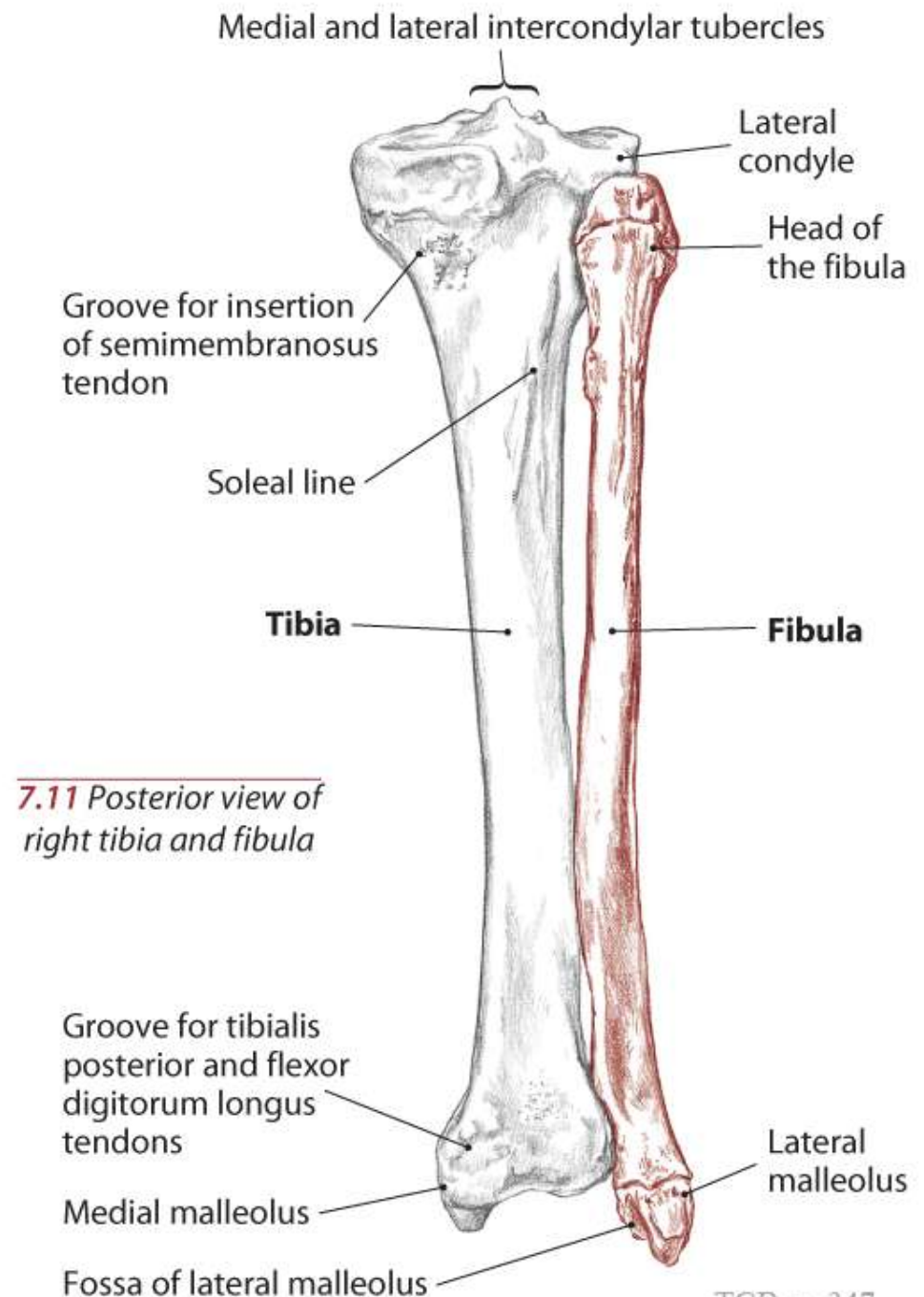
Text



7.10 Anterior view of right tibia and fibula

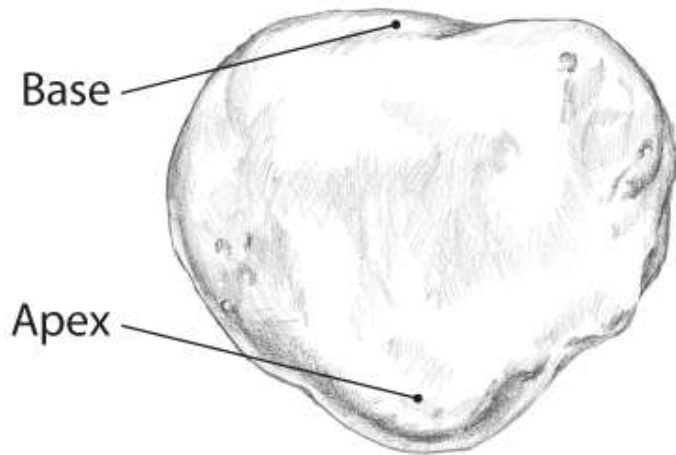
Tibia and Fibula

Text

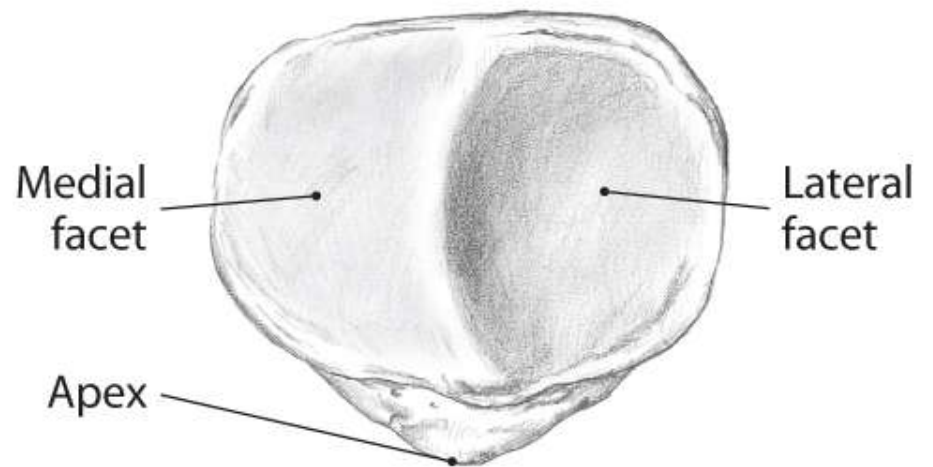


Patella

Text

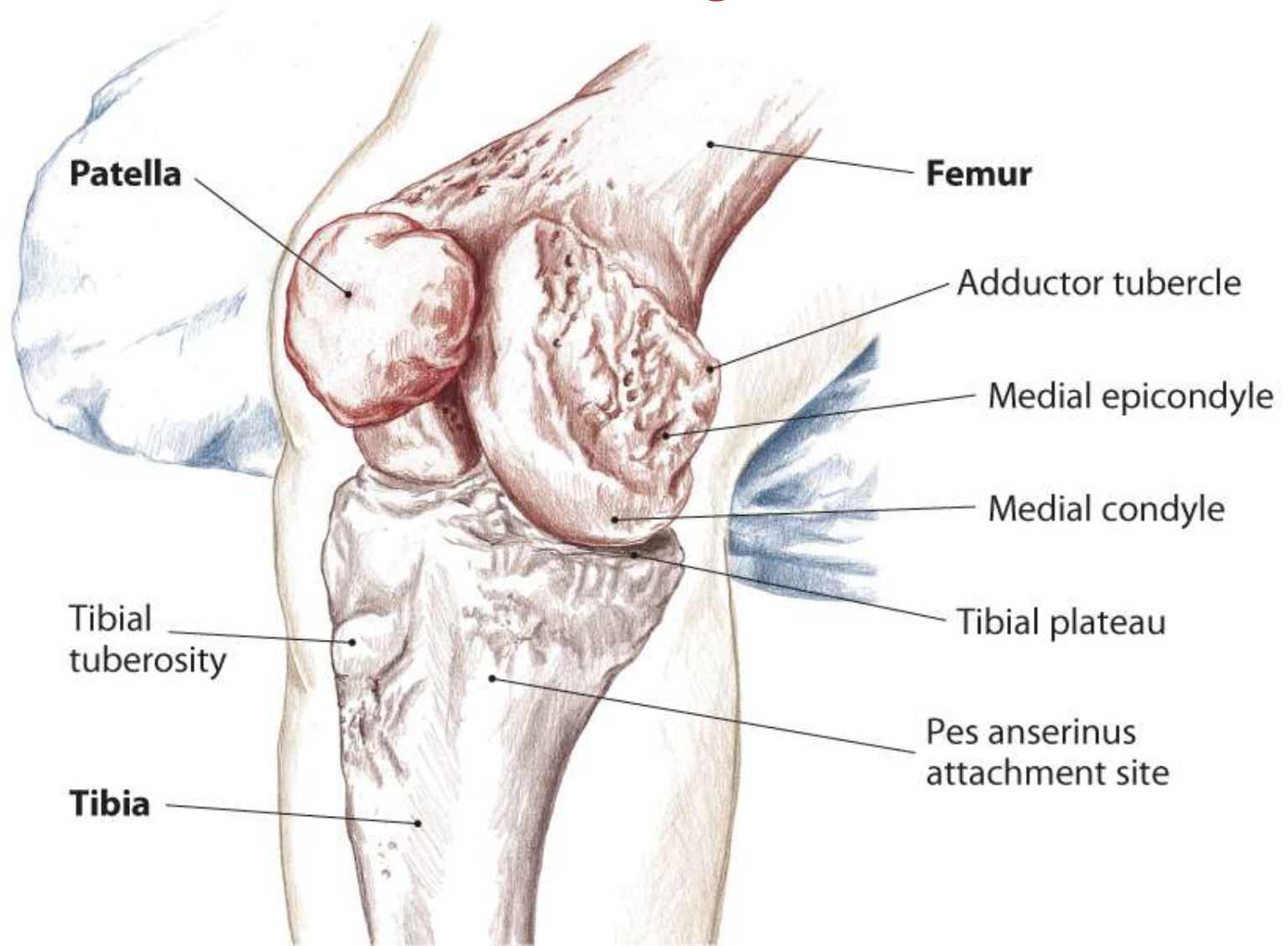


7.12 Anterior view of right patella



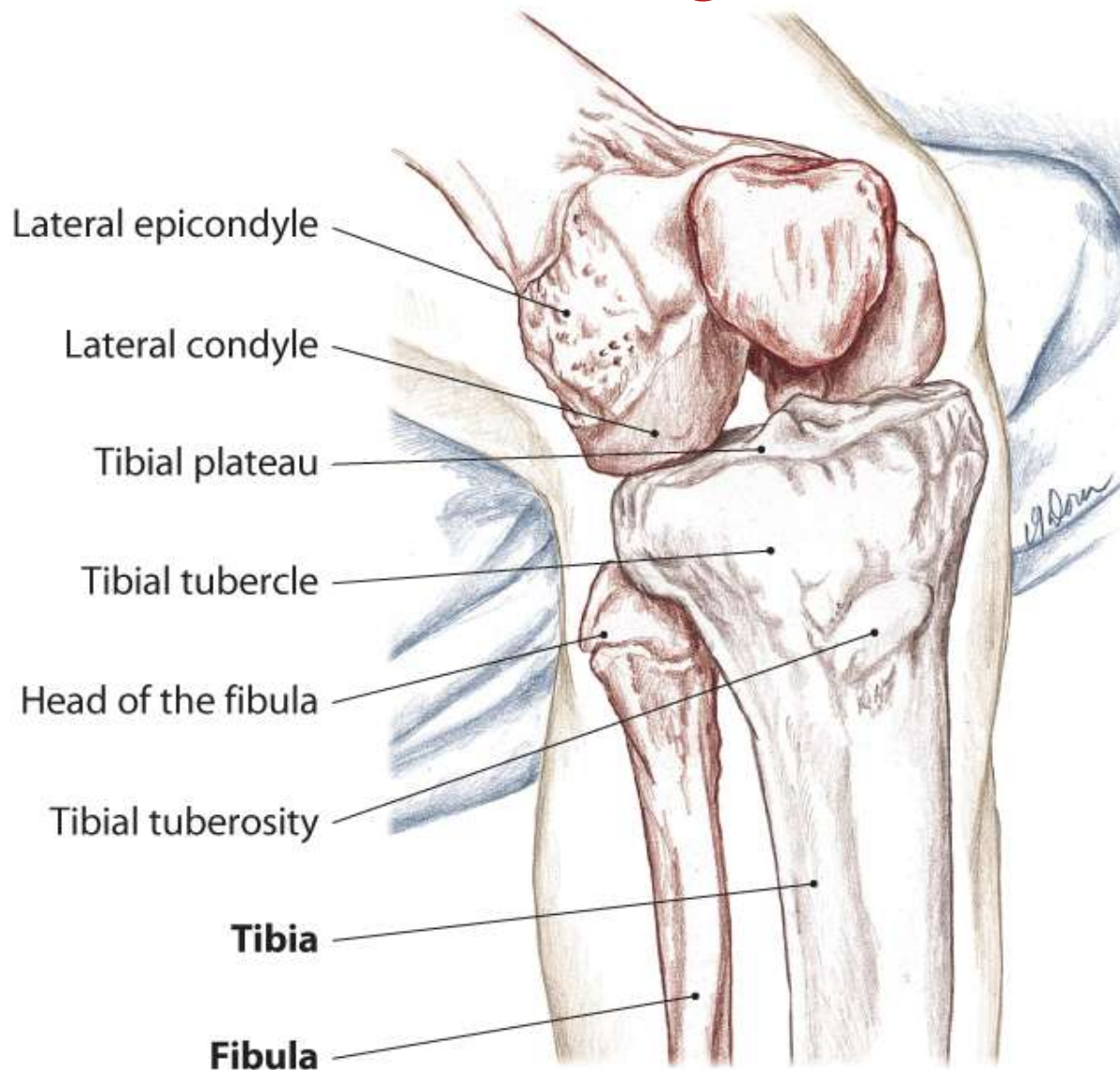
7.13 Posterior view of right patella

Bony Landmarks of the Knee and Leg



7.14 Anterior/medial view of right knee showing tibiofemoral joint

Bony Landmarks of the Knee and Leg



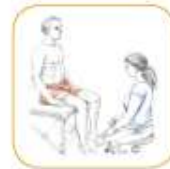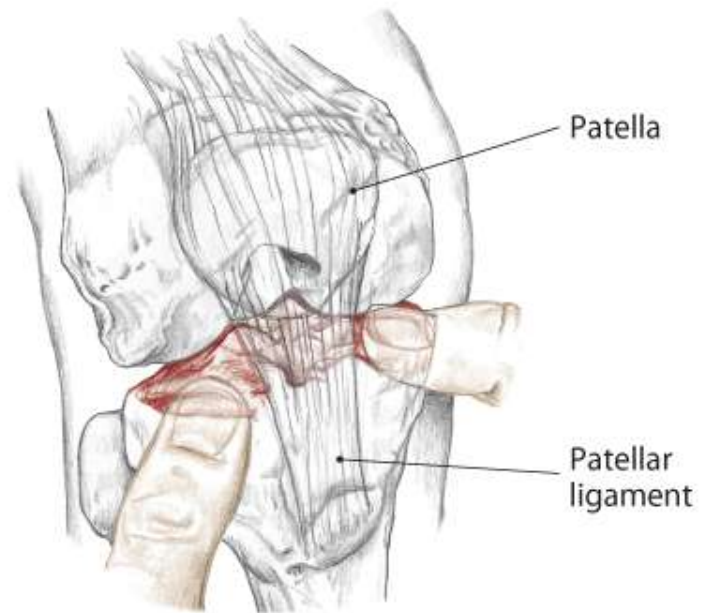
7.15 Anterior/lateral view of right knee showing tibiofemoral joint

Trail 2 “Waddle Walk”

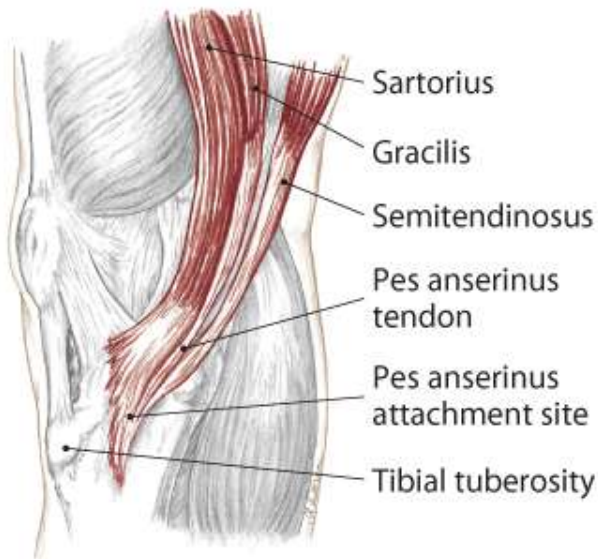
Tibial Plateaus

Pes Anserinus Attachment Site

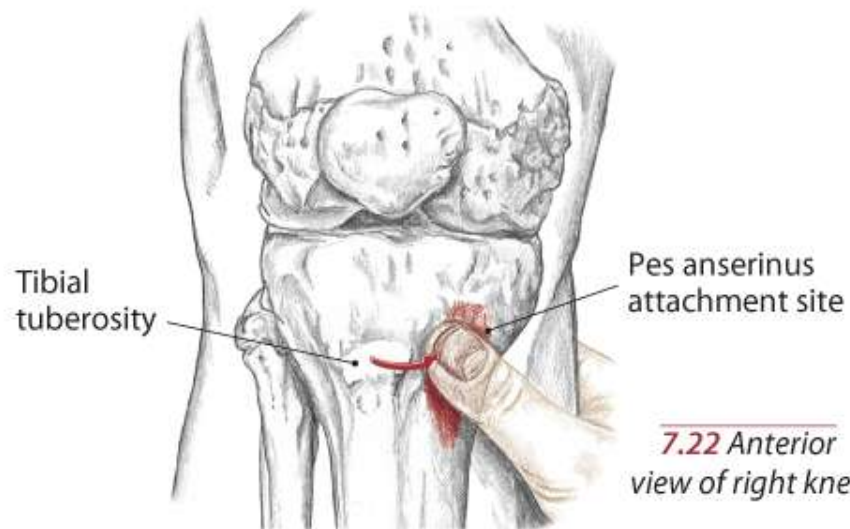
Text



7.20 Anterior view of flexed right knee, accessing the tibial plateaus



7.21 Medial view of right knee



7.22 Anterior view of right knee

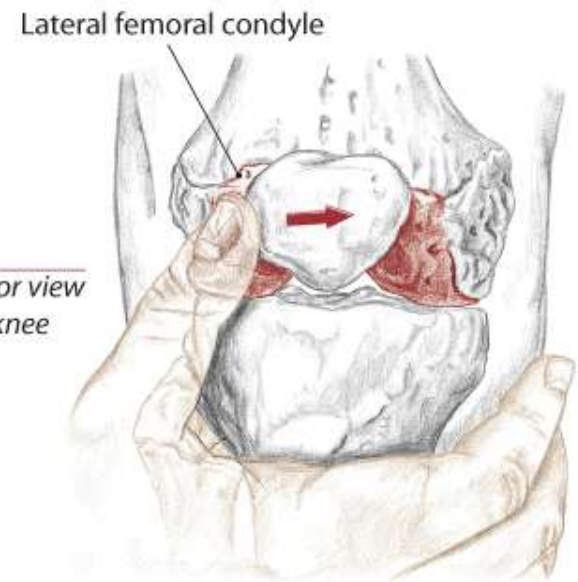
Trail 3 Hills on Both Sides”

Edges of the Femoral Condyles

Epicondyles of the Femur

Adductor Tubercle

7.23 Anterior view
of right knee

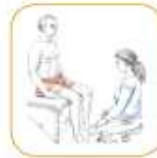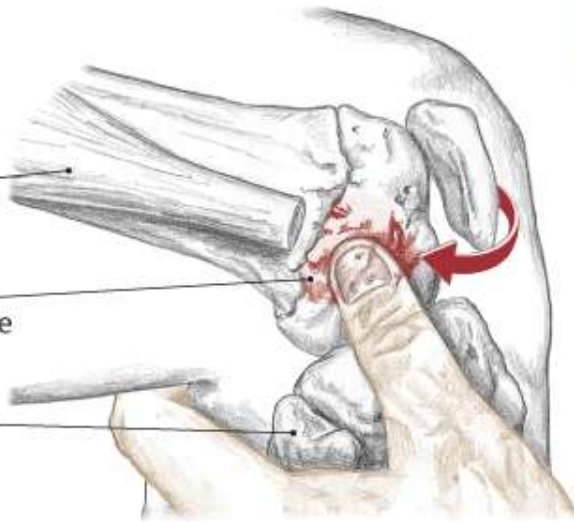


Iliotibial
tract (cut)

Lateral
epicondyle

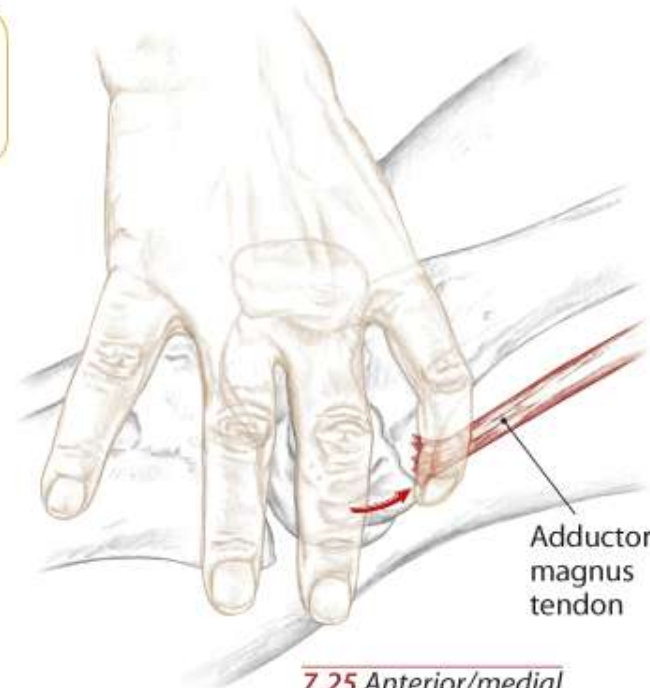
Head of
the fibula

7.24 Lateral view of right knee

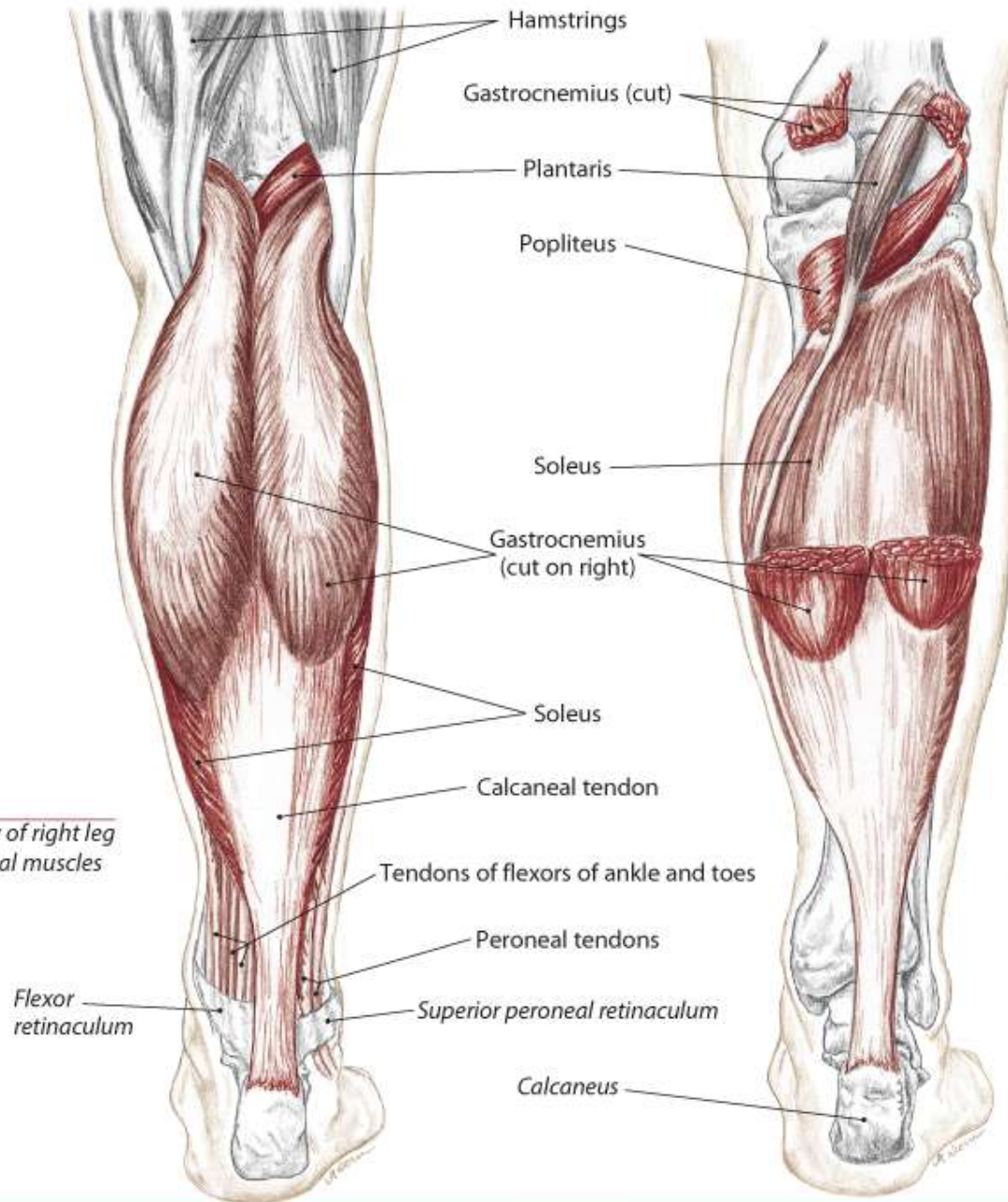


Adductor
magnus
tendon

7.25 Anterior/medial
view of right knee



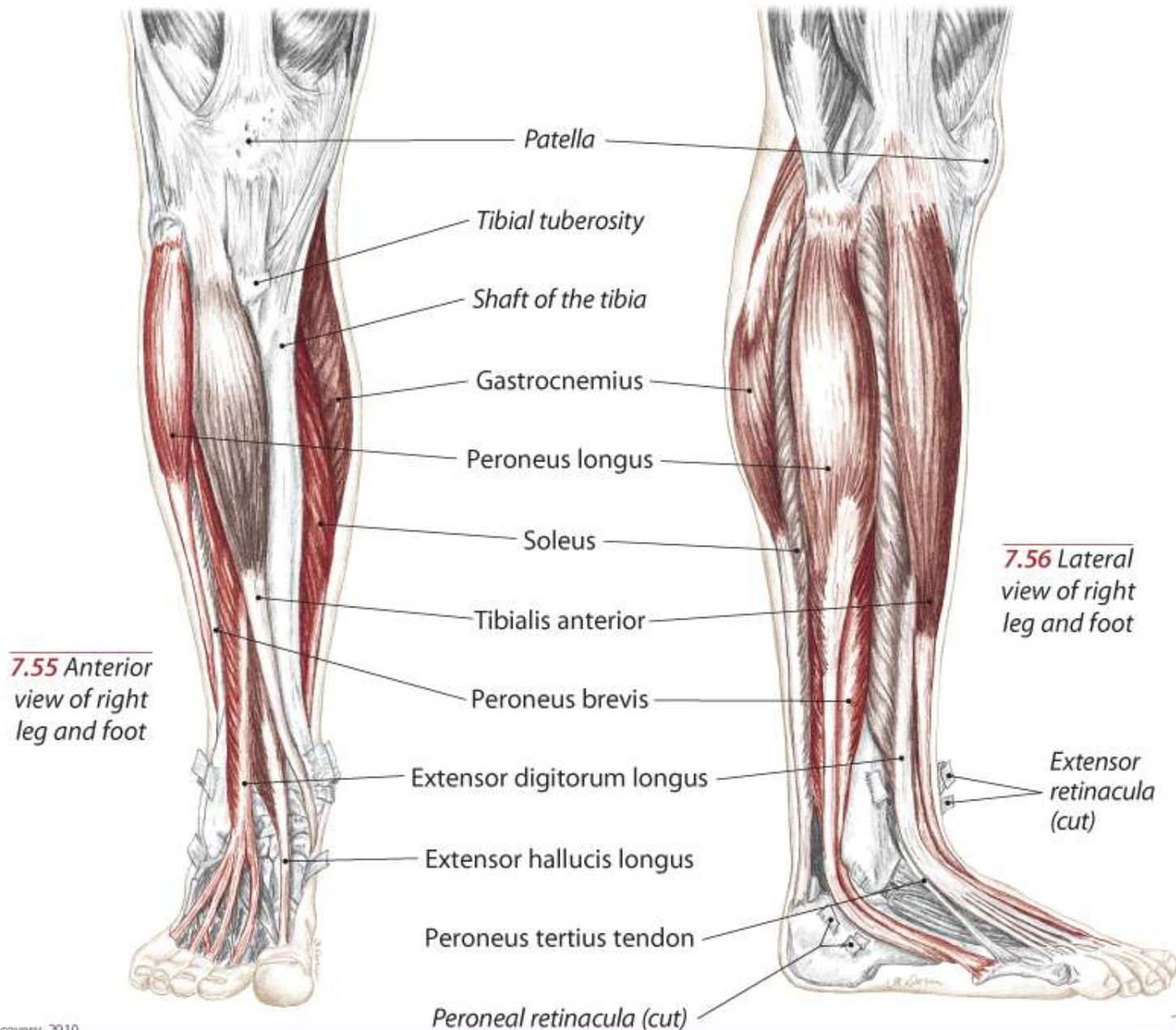
Muscles of the Leg and Foot



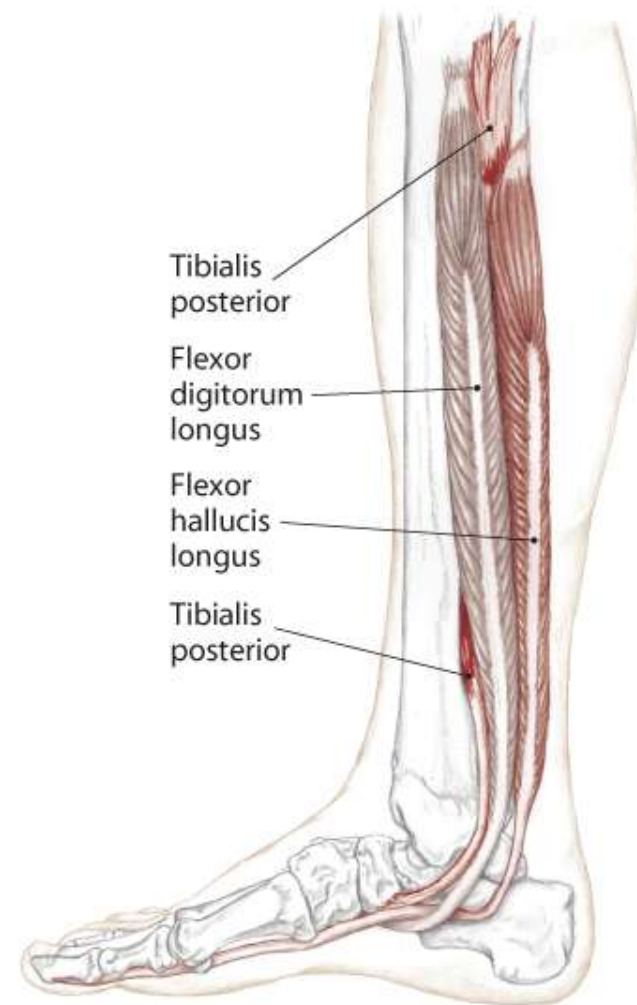
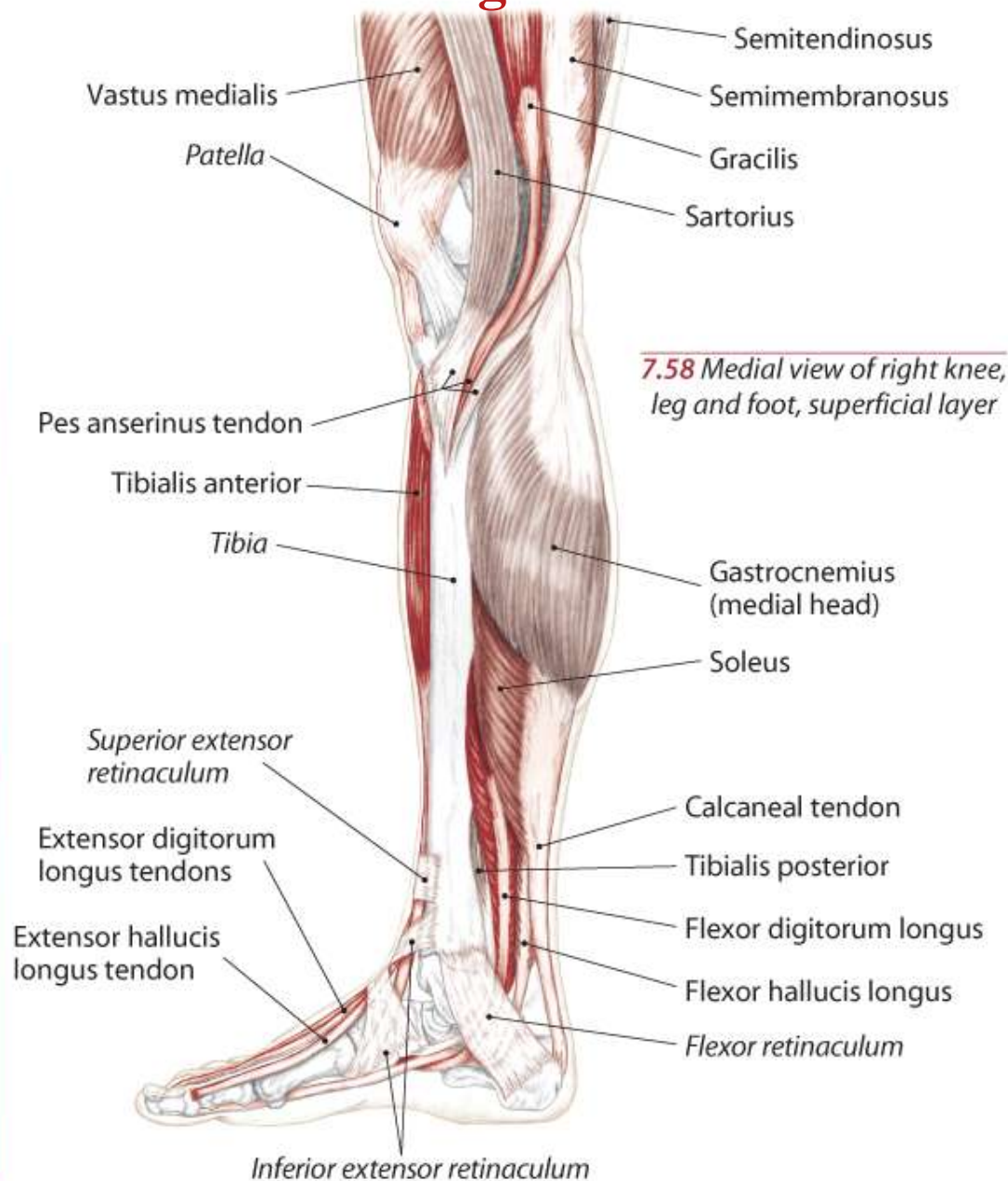
7.53 Posterior view of right leg showing superficial muscles

7.54 Posterior view of right leg showing deeper muscles

Muscles of the Leg and Foot



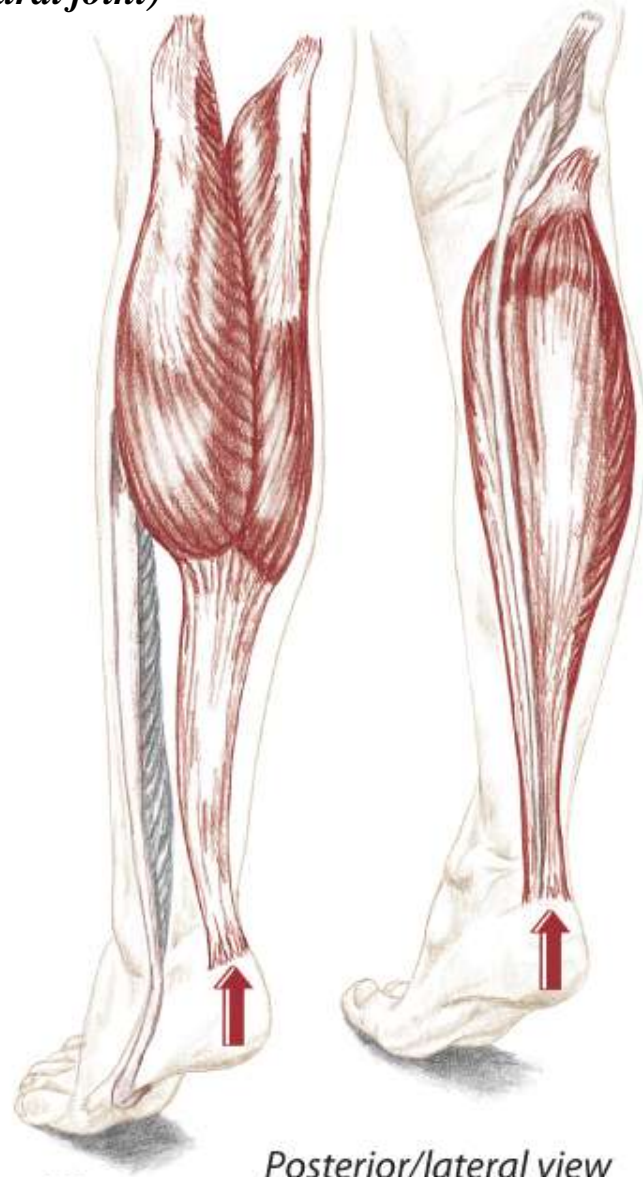
Muscles of the Leg and Foot



Synergists – Muscles Working Together

Ankle

(talocrural joint)



Posterior/lateral view

Plantar Flexion

(antagonists on dorsiflexion)

Gastrocnemius

Soleus

Tibialis posterior

Peroneus longus (assists)

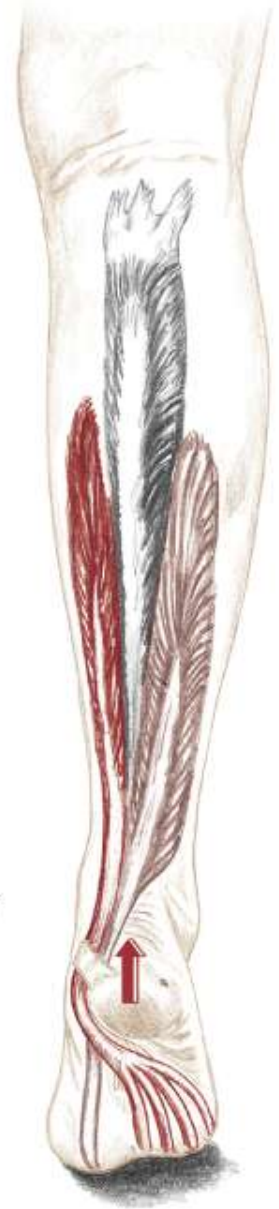Peroneus brevis (assists)

Flexor digitorum longus (weak)

Flexor hallucis longus (weak)

Plantaris (weak)

Posterior view



Ankle

(talocrural joint)

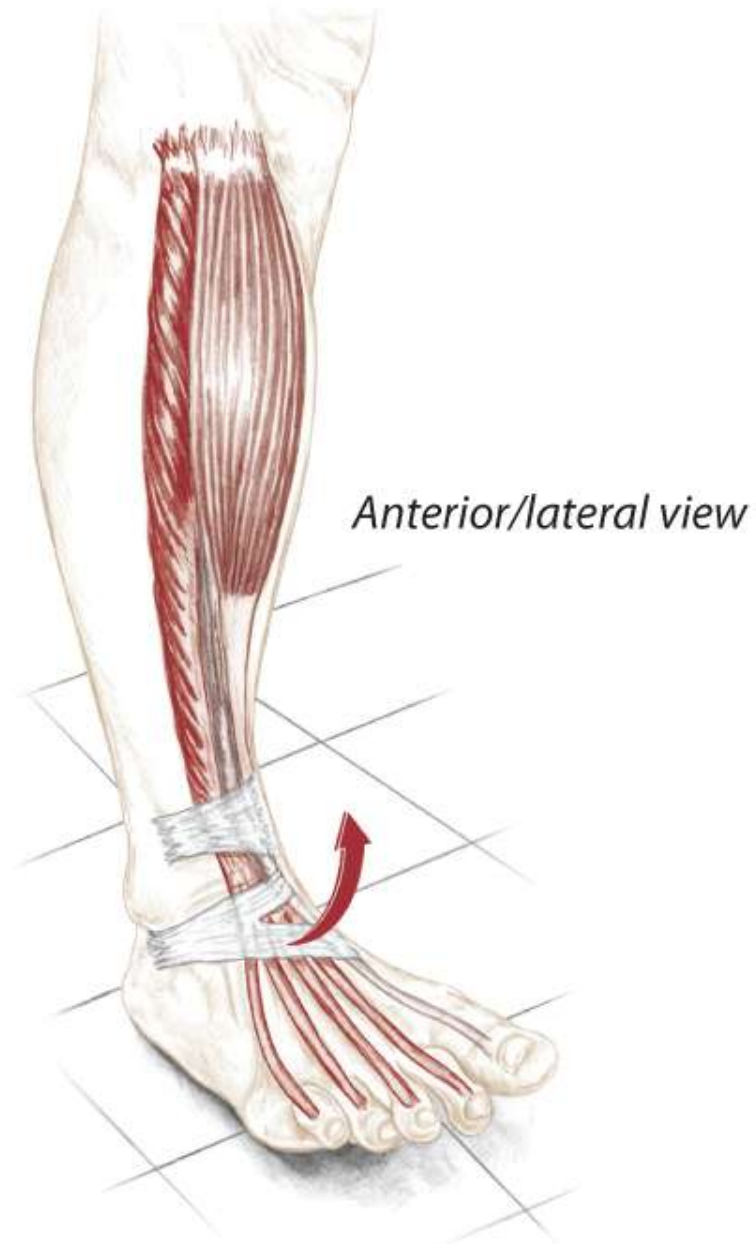
Dorsiflexion

(antagonists on plantar flexion)

Tibialis anterior

Extensor digitorum longus

Extensor hallucis longus



Gastrocnemius and Soleus

Gastrocnemius

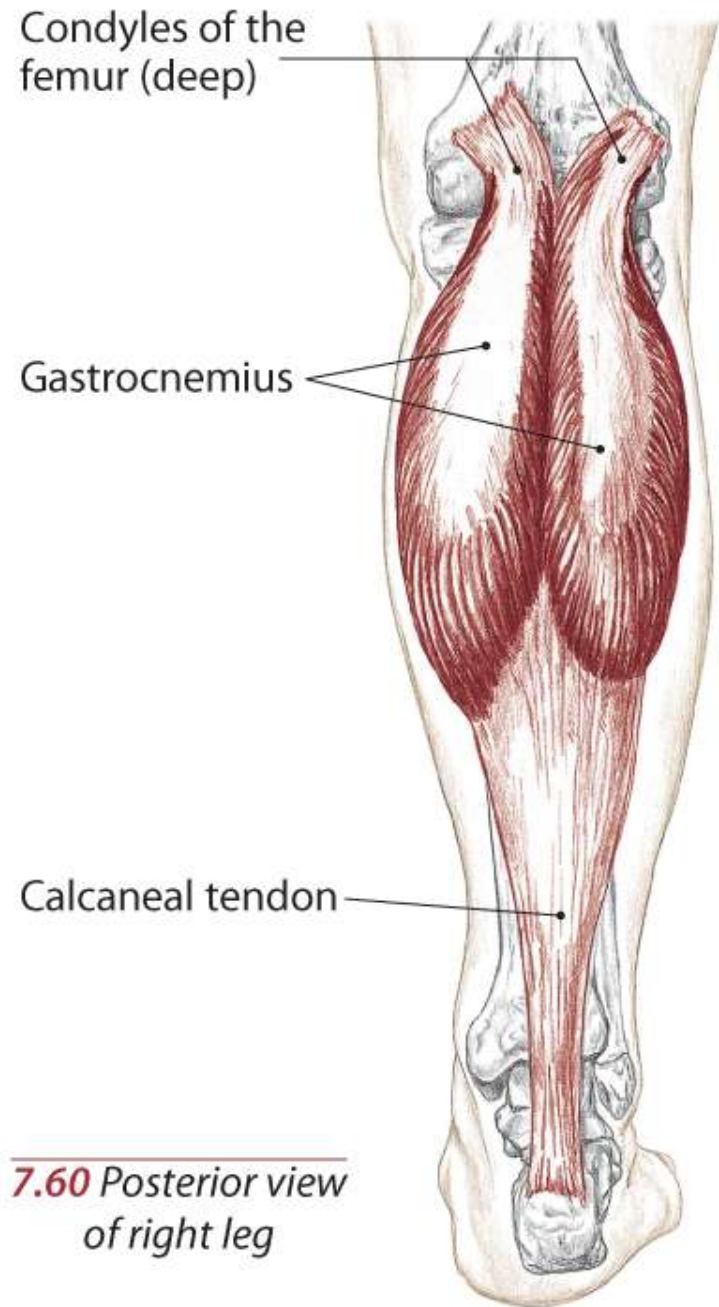
A **Flex** the knee (tibiofemoral joint)

Plantar flex the ankle (talocrural joint)

O Condyles of the femur, posterior surfaces

I Calcaneus via calcaneal tendon

N Tibial S1, 2

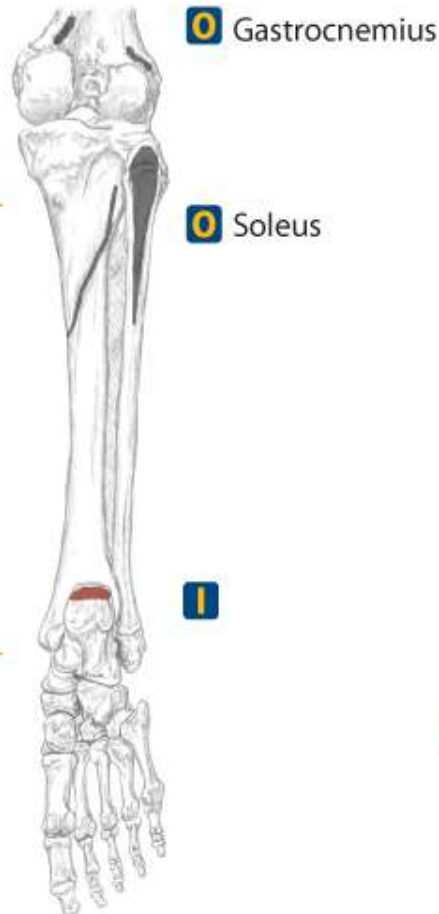


7.60 *Posterior view
of right leg*

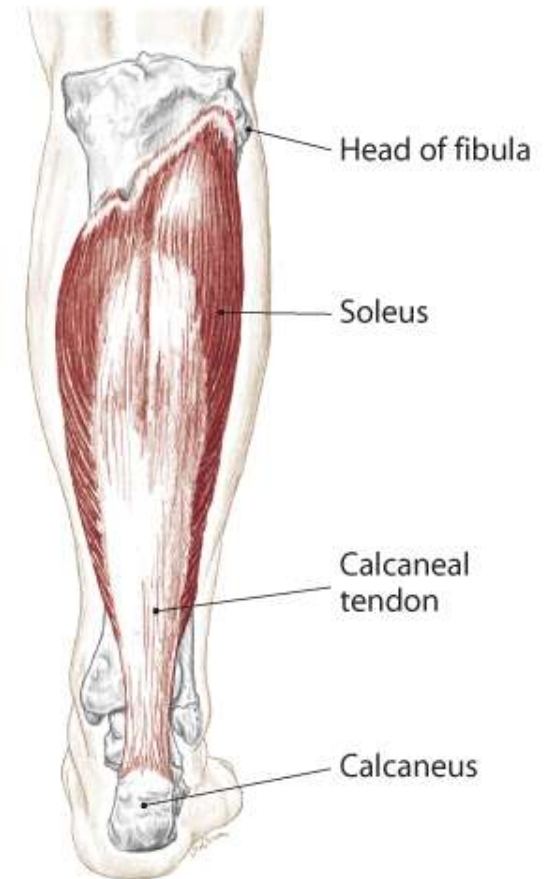
Gastrocnemius and Soleus

Soleus

- A** **Plantar flex** the ankle (talocrural joint)
- O** Soleal line; proximal, posterior surface of tibia and posterior aspect of head of fibula
- I** Calcaneus via calcaneal tendon
- N** Tibial L5, S1, 2

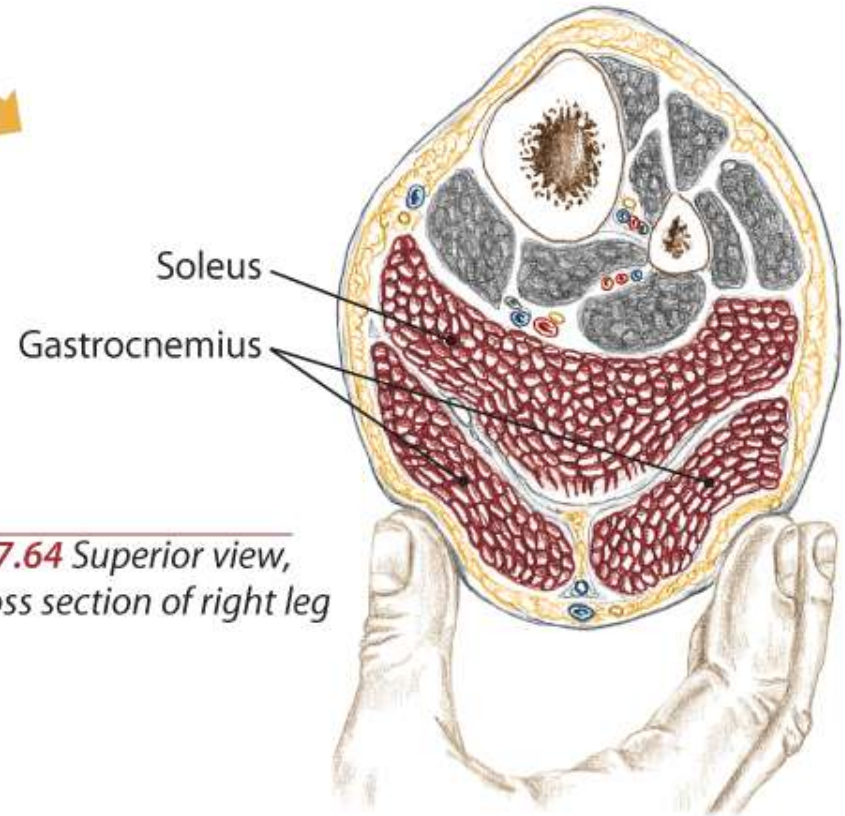
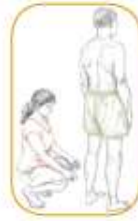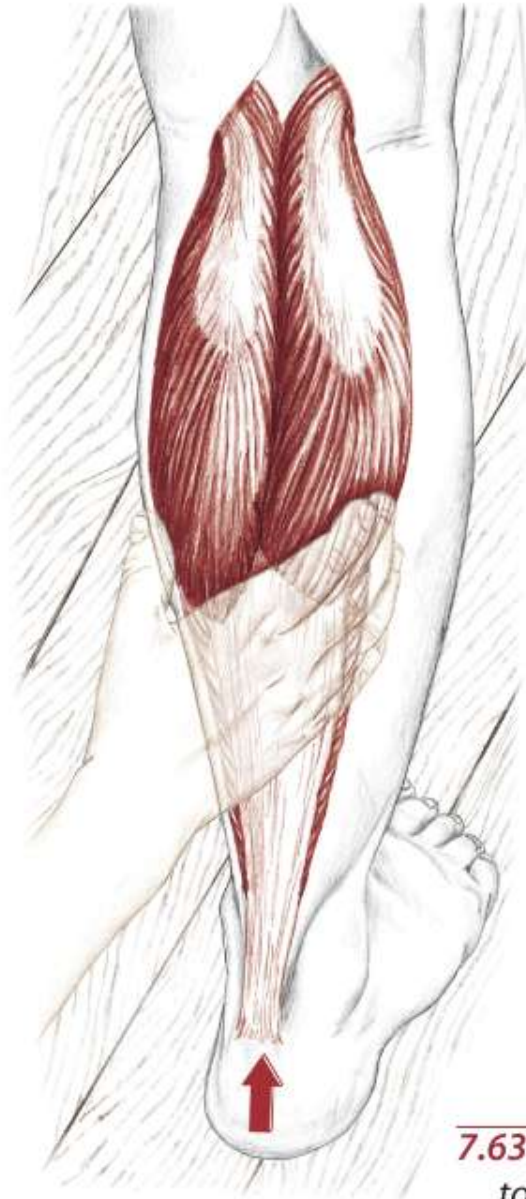


7.61 Posterior view of right leg with foot plantar flexed, showing origins and insertions



7.62 Posterior view of right leg, with gastrocnemius removed

Gastrocnemius and Soleus - Standing

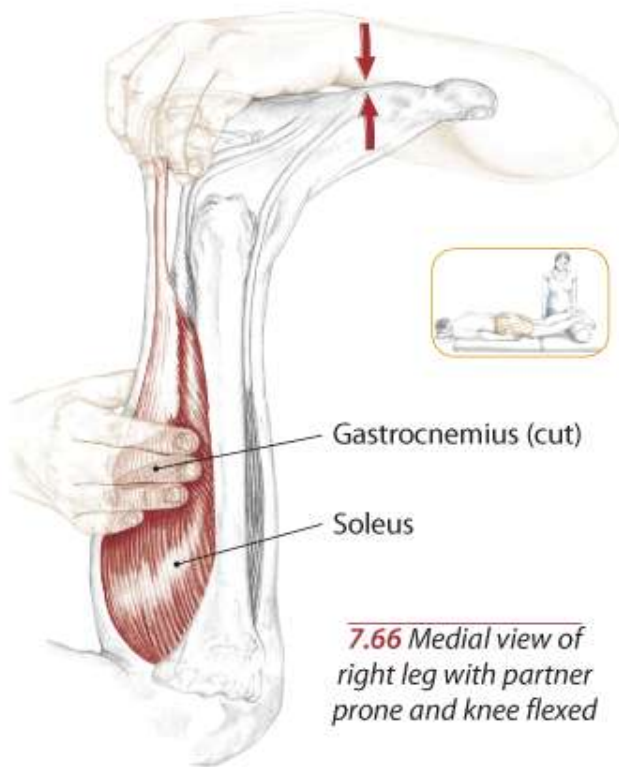


7.64 Superior view,
cross section of right leg

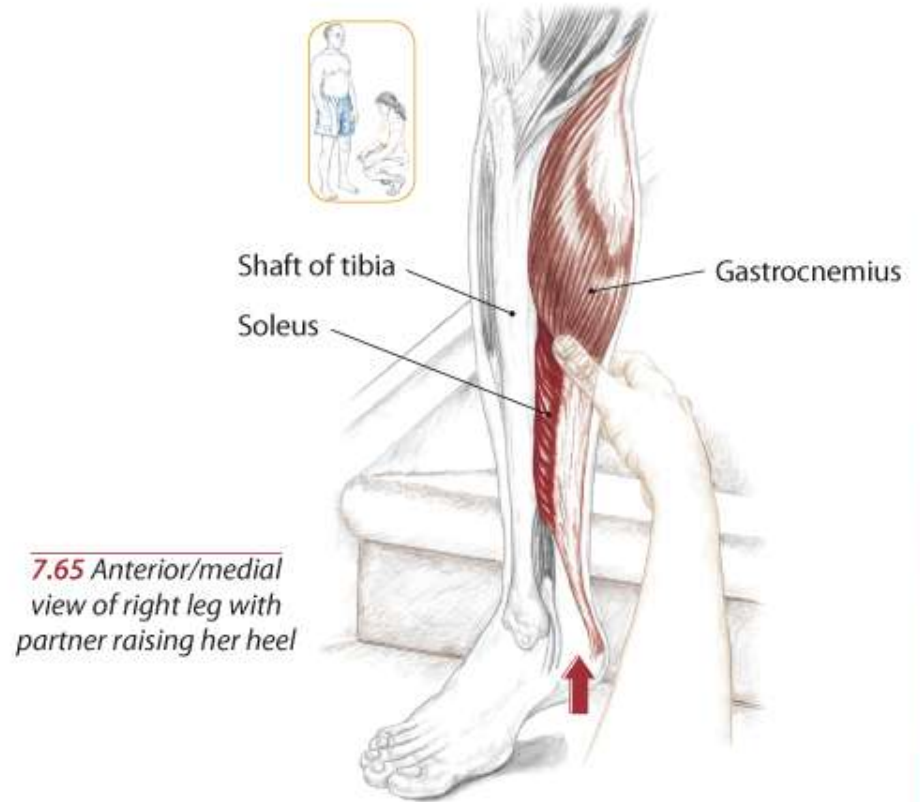
7.63 Partner raising her heel
to stand up on her toes

Gastrocnemius and Soleus

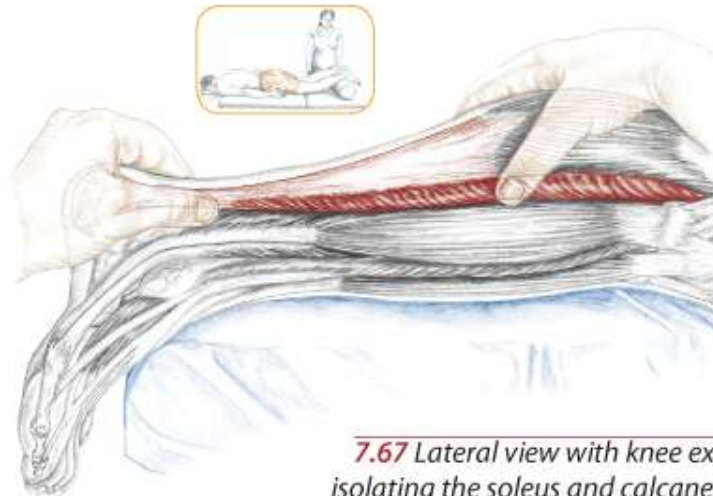
Text



7.66 Medial view of right leg with partner prone and knee flexed



7.65 Anterior/medial view of right leg with partner raising her heel



7.67 Lateral view with knee extended, isolating the soleus and calcaneal tendon

Plantaris

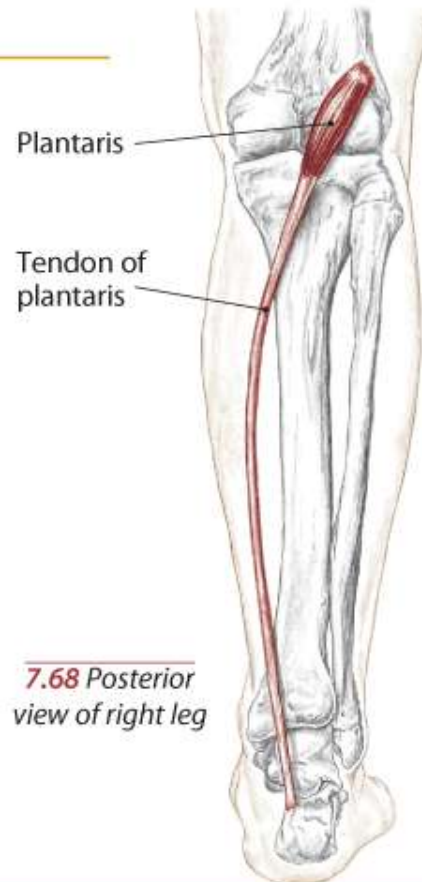
A Weak **plantar flexion** of the ankle (talocrural joint)

Weak **flexion** of the knee (tibiofemoral joint)

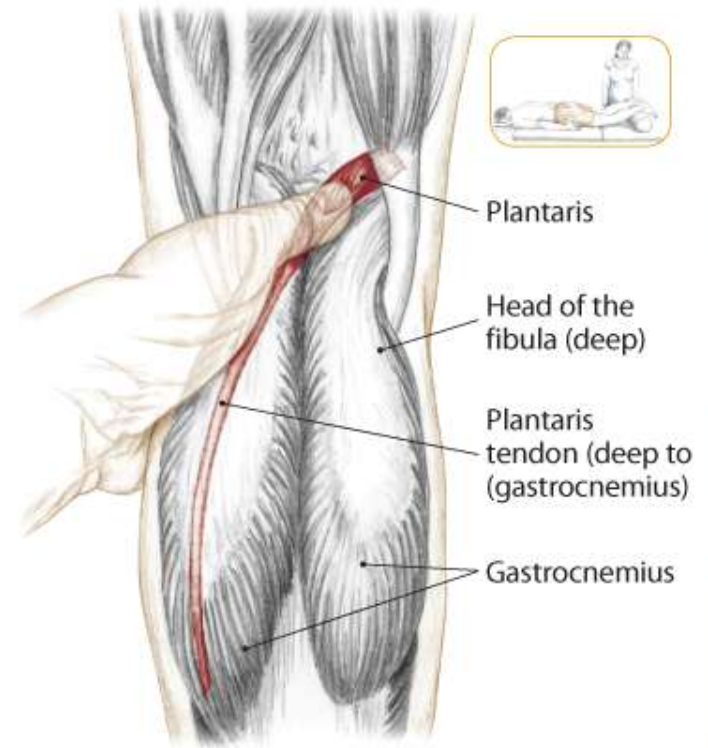
O Lateral supracondylar line of femur

I Calcaneus via calcaneal tendon

N Tibial L4, 5, S1, (2)



7.68 Posterior view of right leg



7.69 Posterior view of right knee

Popliteus

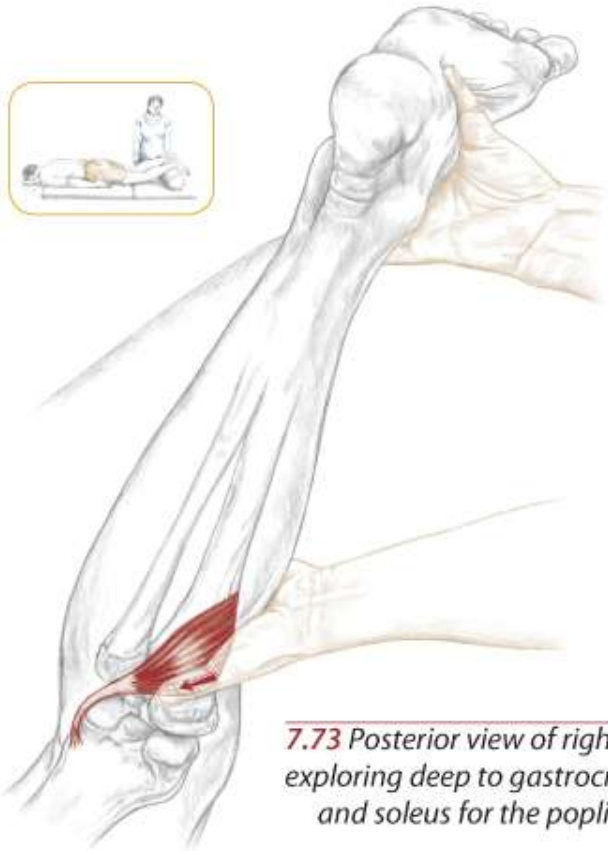
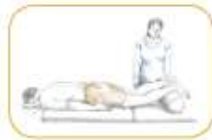A Medially rotate the flexed knee (tibiofemoral joint)

Flex the knee (T/F joint)

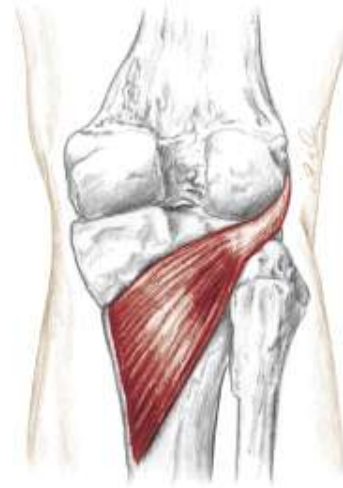O Lateral condyle of the femur

I Proximal, posterior aspect of tibia

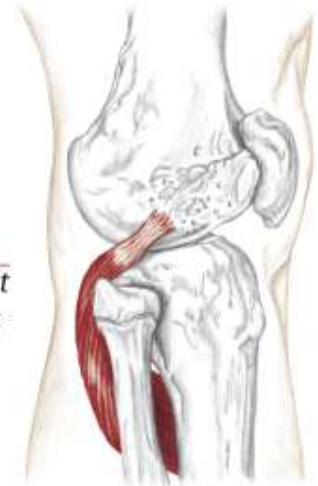
N Tibial L4, 5, S1



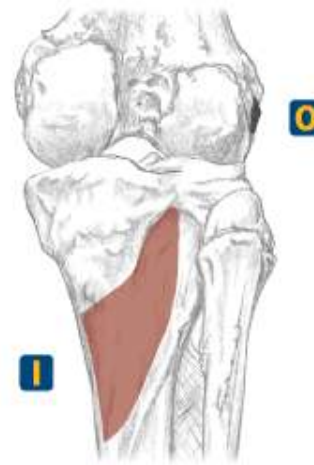7.73 Posterior view of right knee, exploring deep to gastrocnemius and soleus for the popliteus



7.70 Posterior view of right knee showing the popliteus



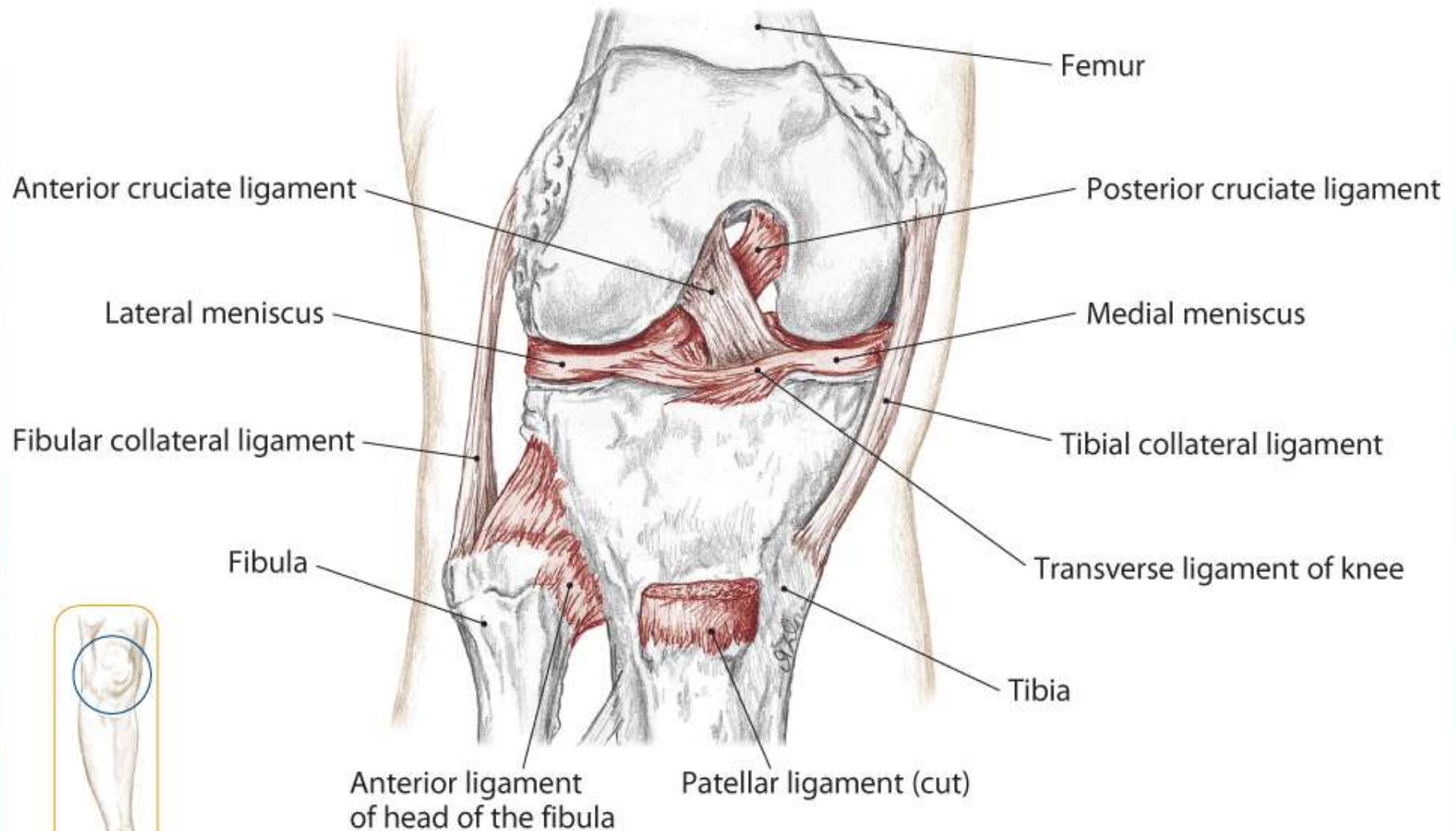
7.71 Lateral view of right knee showing popliteus



7.72 Origin and insertion

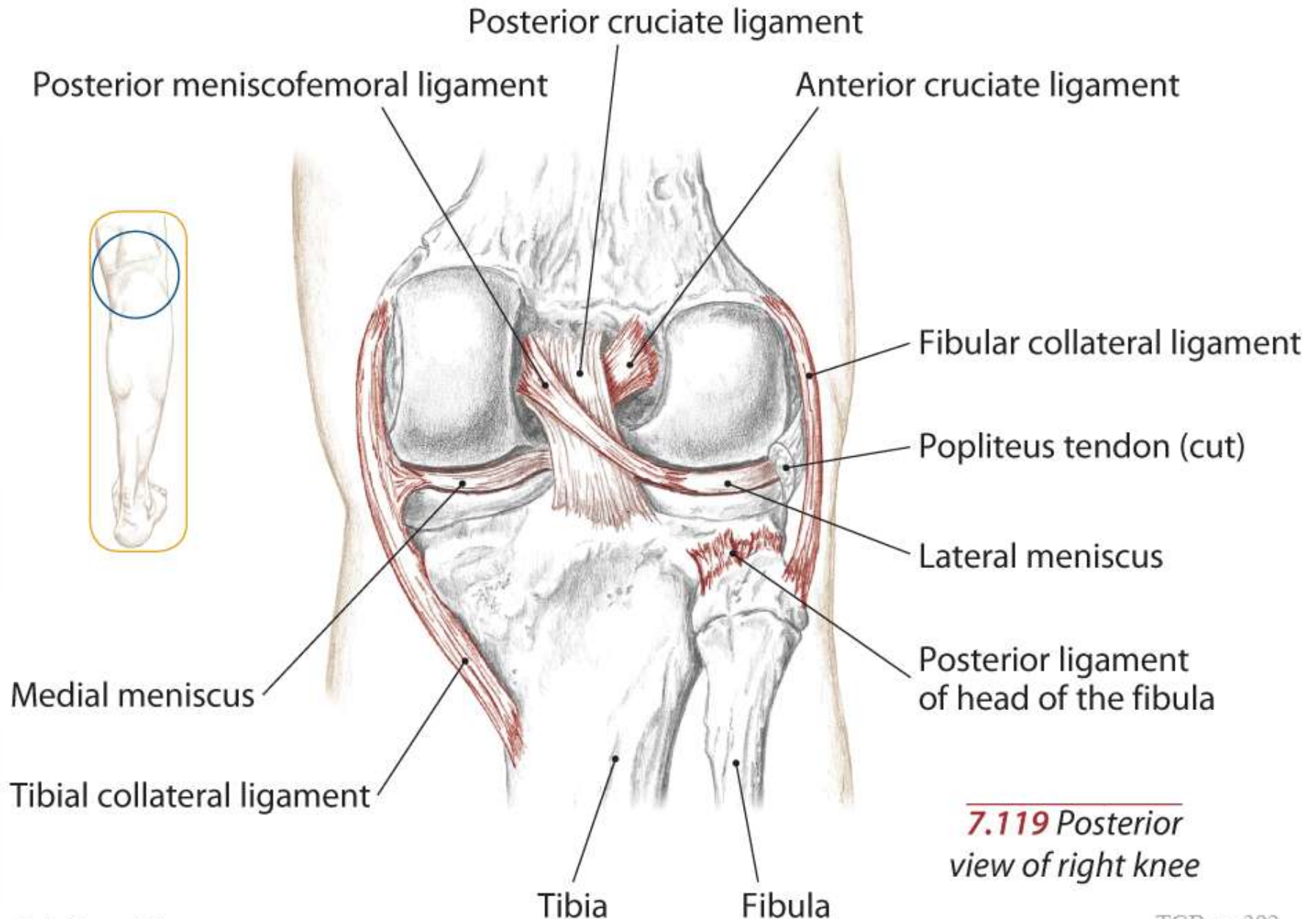
Other Structures of the Knee and Leg

Tibiofemoral Joint



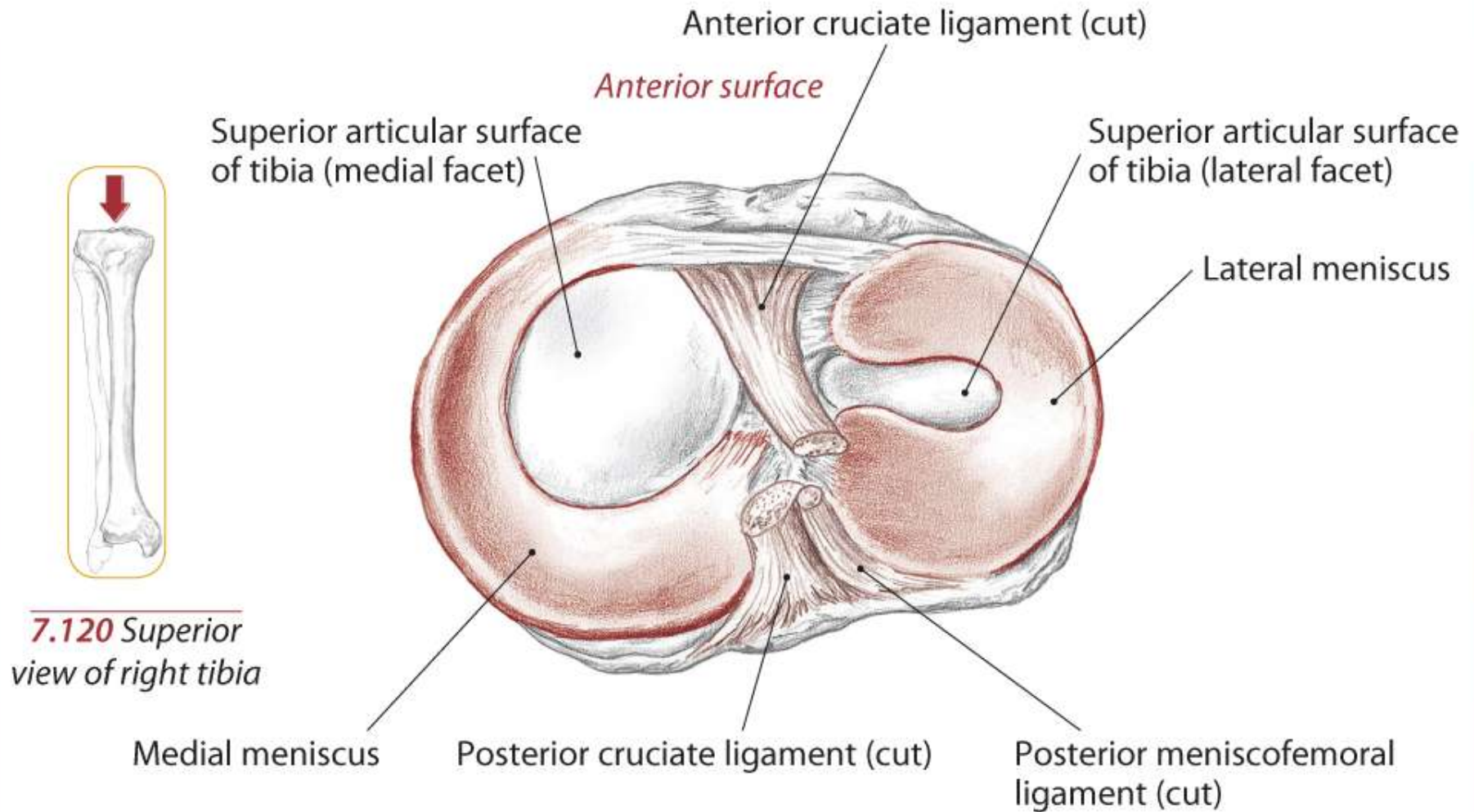
7.118 Anterior view of right knee with patella removed

Tibiofemoral Joint



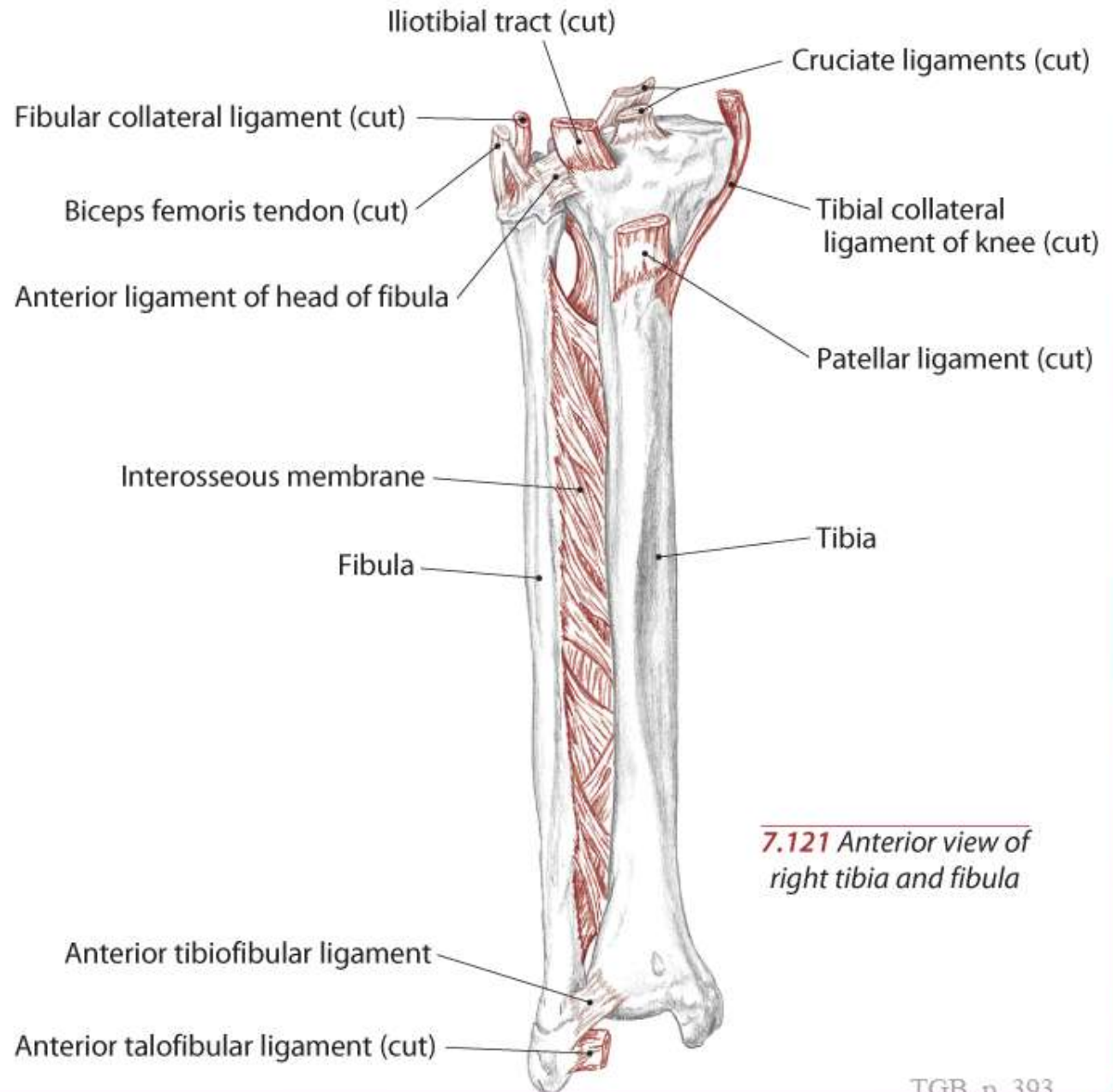
7.119 *Posterior view of right knee*

Tibiofemoral Joint



Tibiofemoral and Tibiofibular Joints

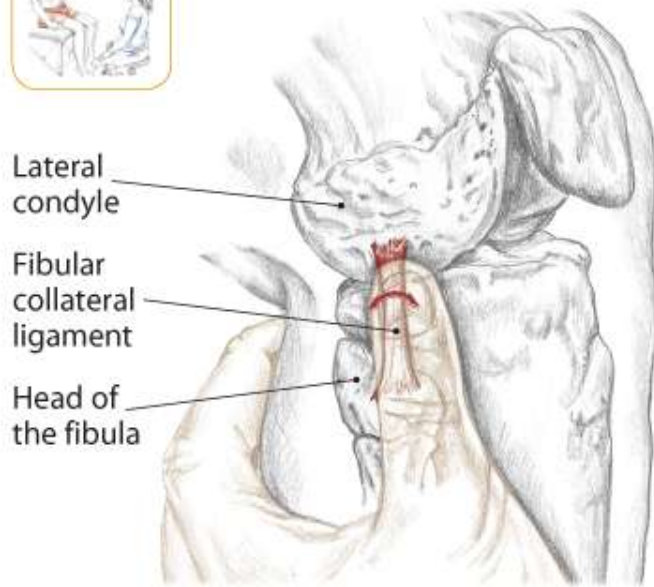
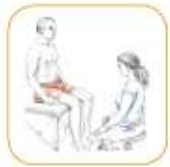Text



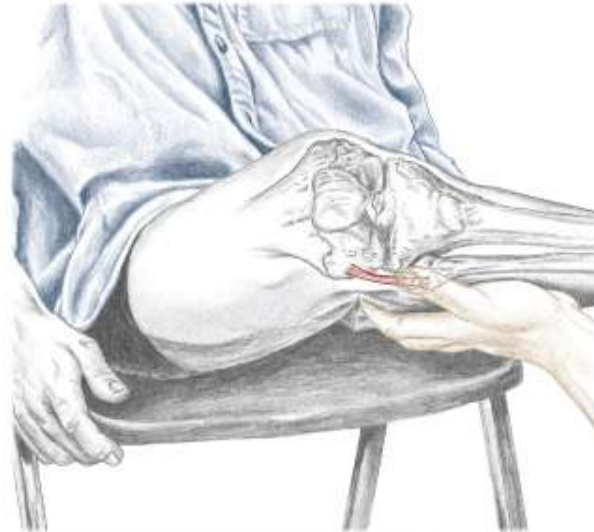7.121 Anterior view of
right tibia and fibula

Fibular Collateral Ligament

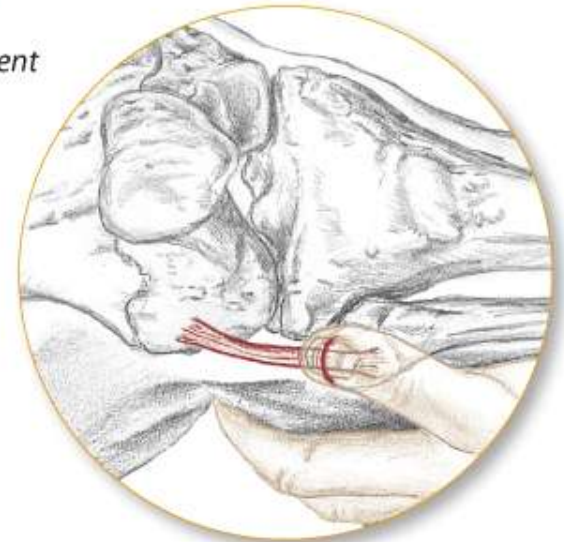
Text



7.122 Lateral view of right knee



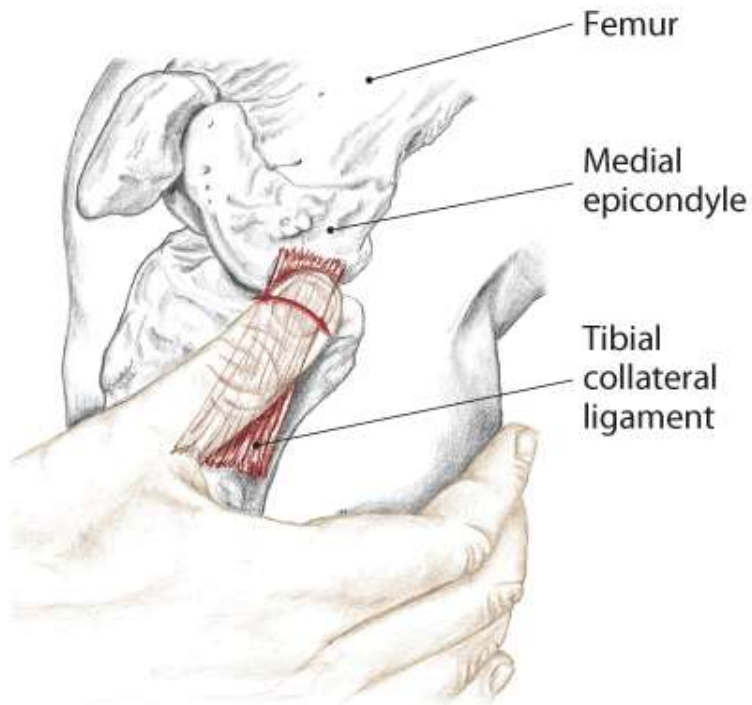
7.123 An alternate method to locating the fibular collateral ligament



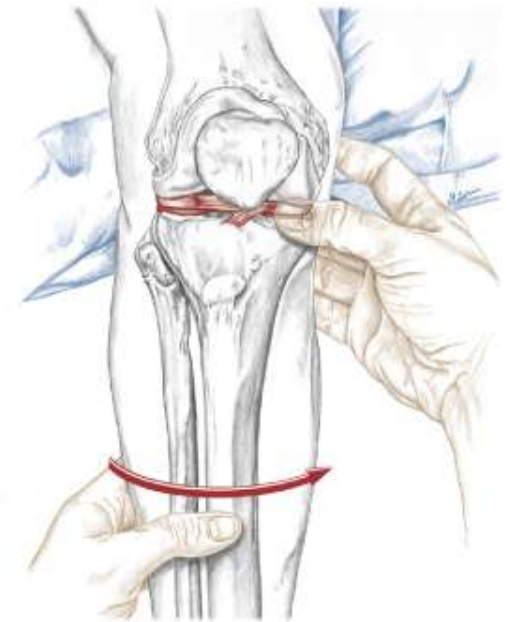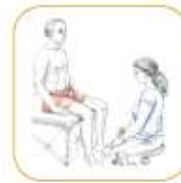Tibial Collateral Ligament

Menisci of the Knee

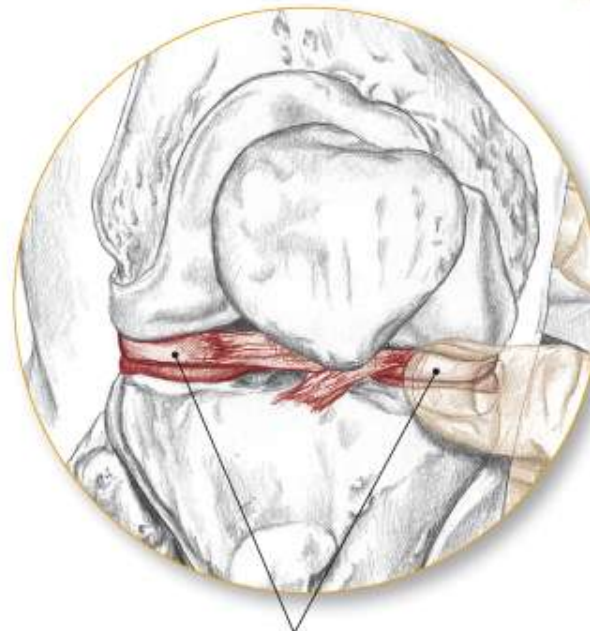Text



7.124 Medial view of right knee



7.125 Anterior view of flexed right knee



Menisci

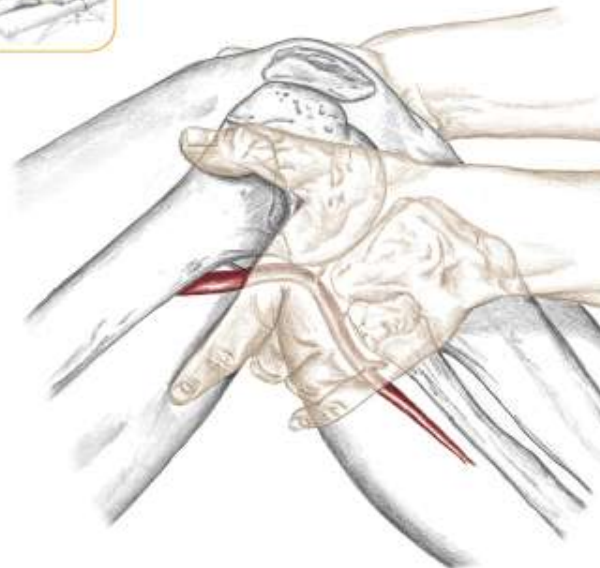
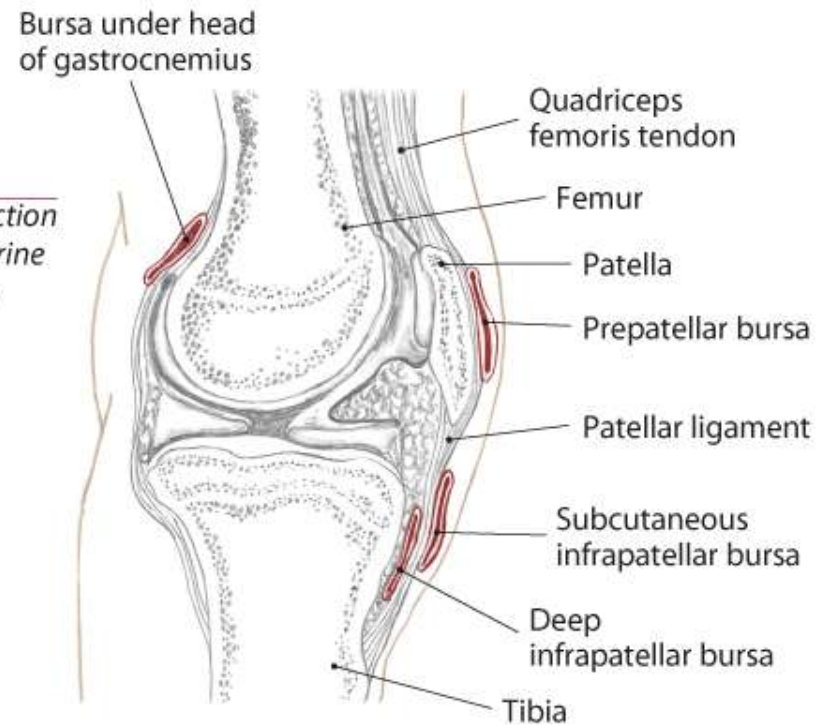
Bursae of the Knee

Text

Popliteal Artery

Text

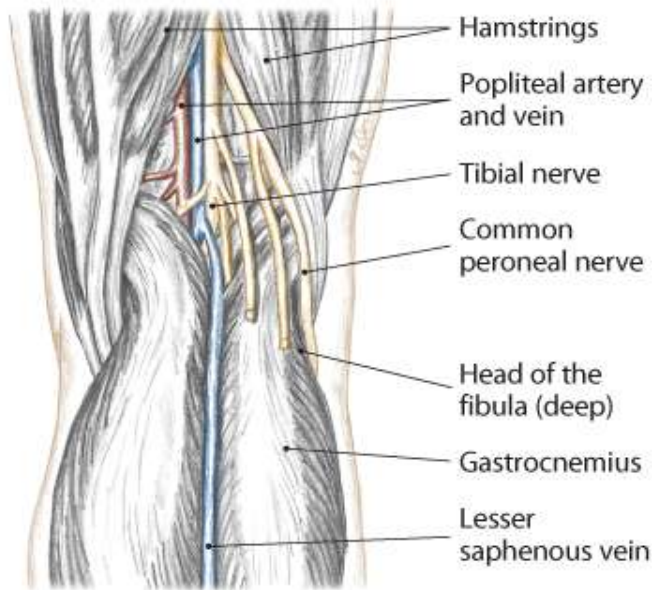
7.126 Lateral cross section of the knee, pes anserine bursa not shown



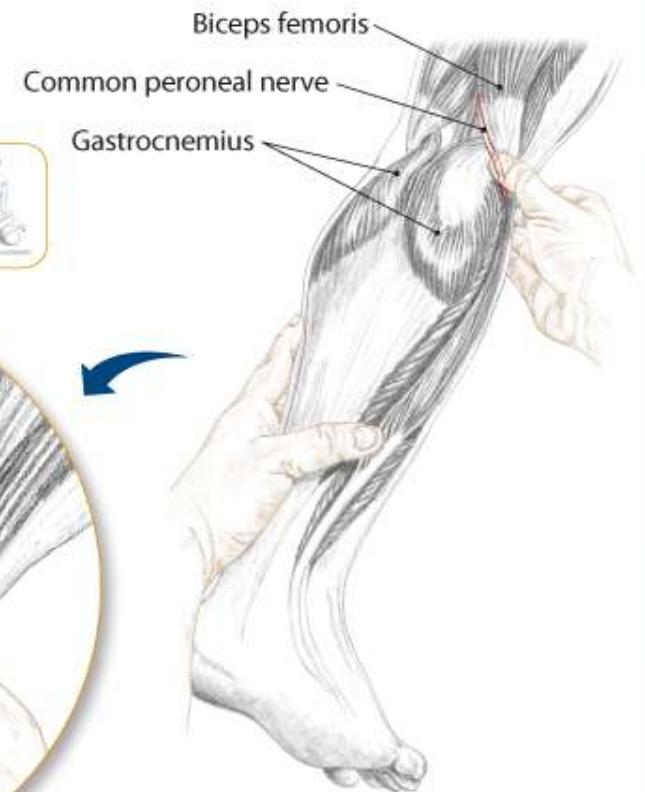
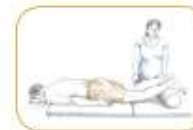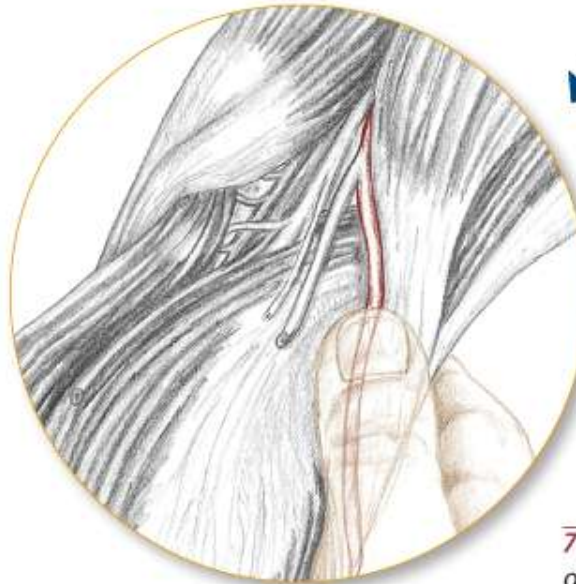
7.127 Lateral view of right knee, feeling the pulse of the popliteal artery

Common Peroneal Nerve

Text



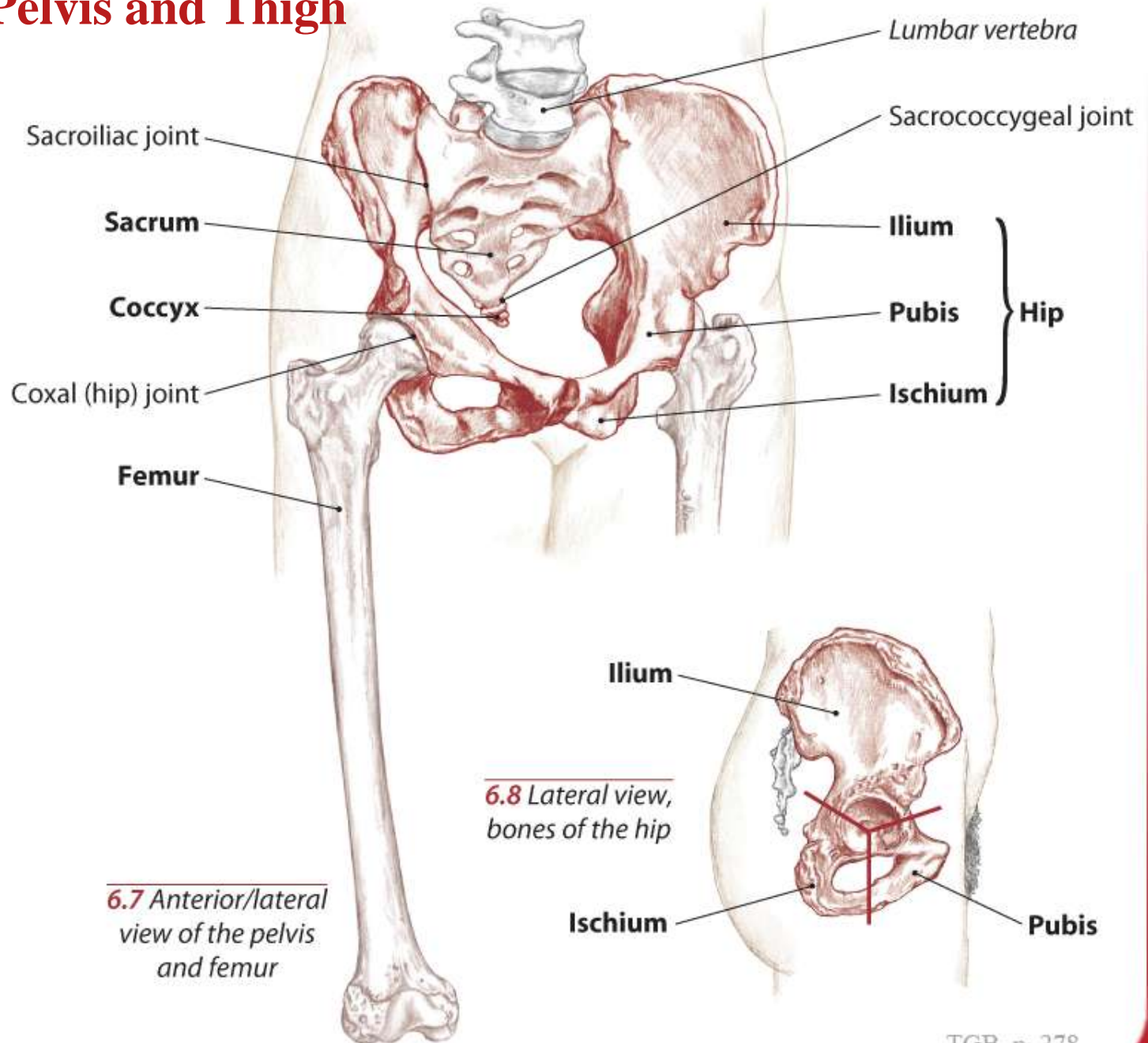
7.128 Posterior view of right knee



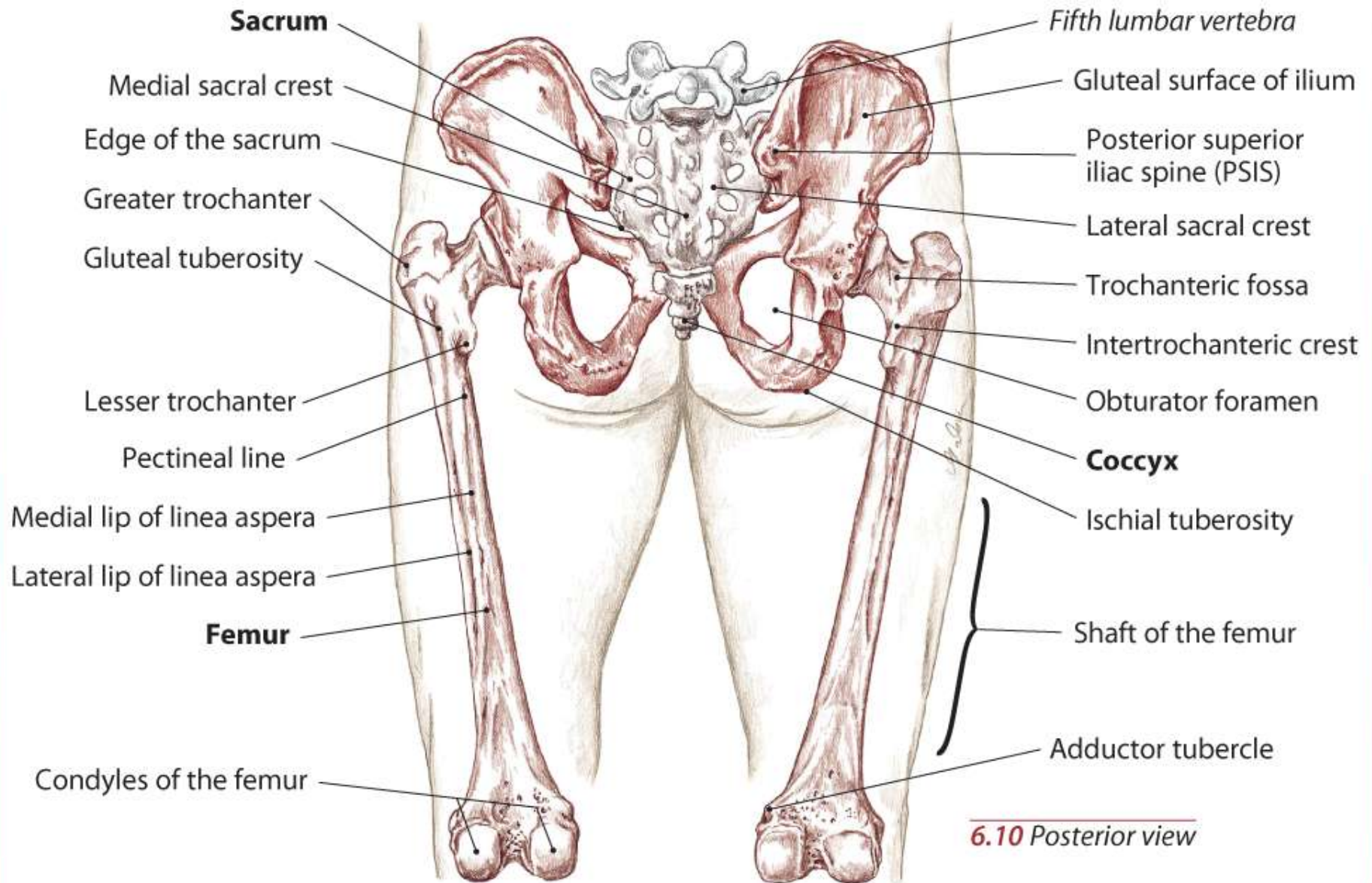
7.129 Posterior/lateral view of right knee, partner prone

Bones of the Pelvis and Thigh

Text



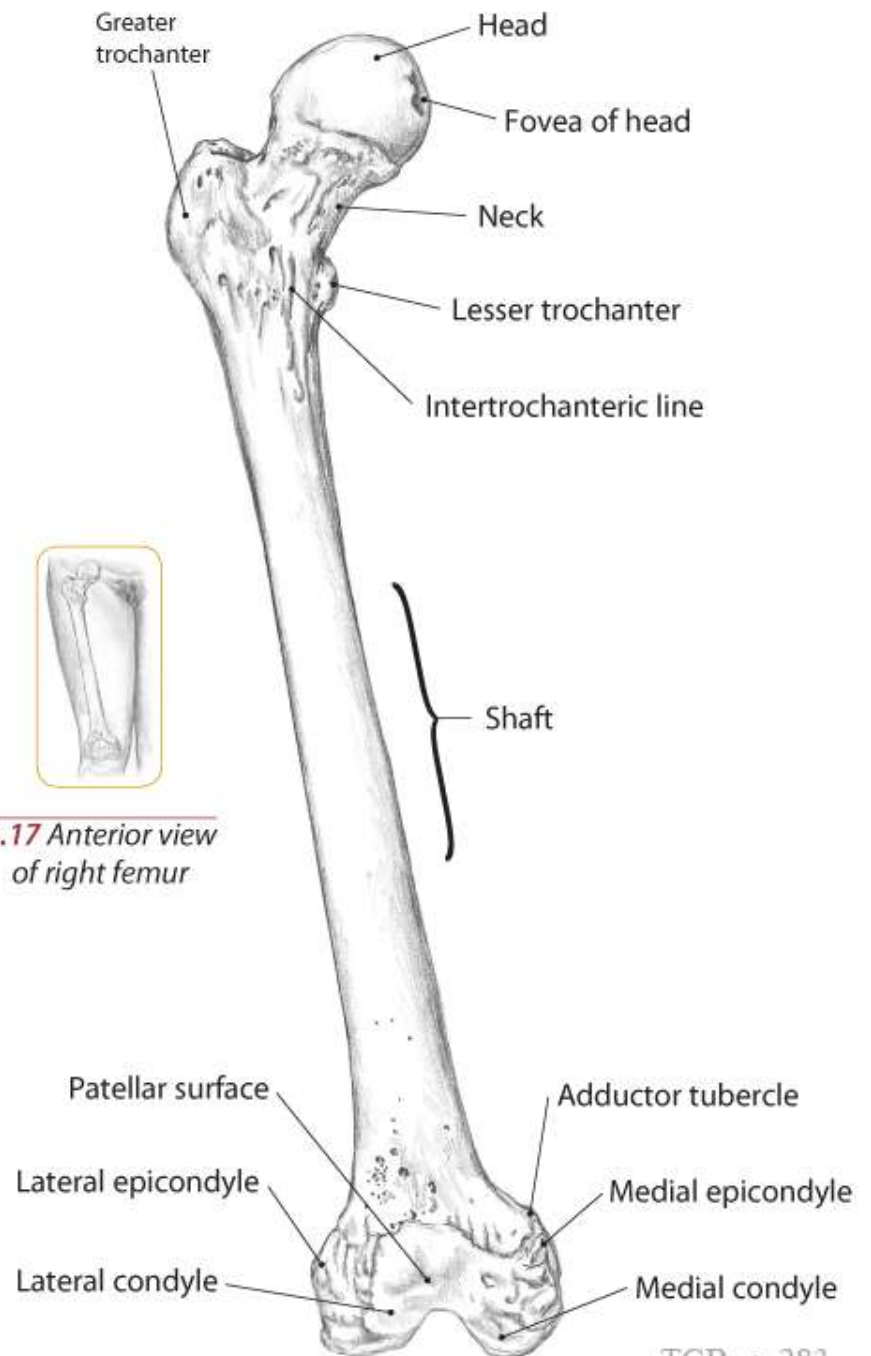
Bony Landmarks



6.10 Posterior view

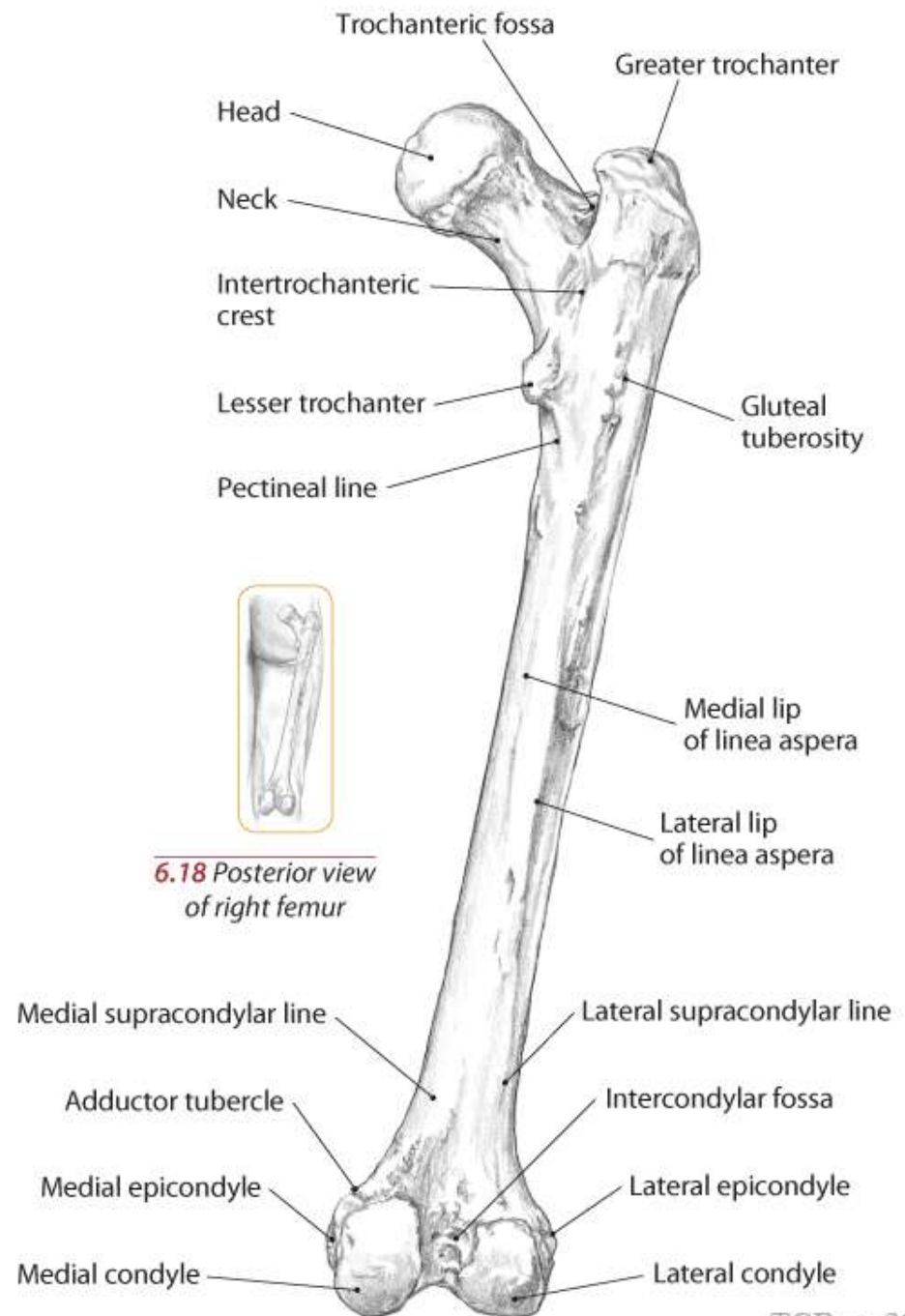
Bony Landmarks

Text



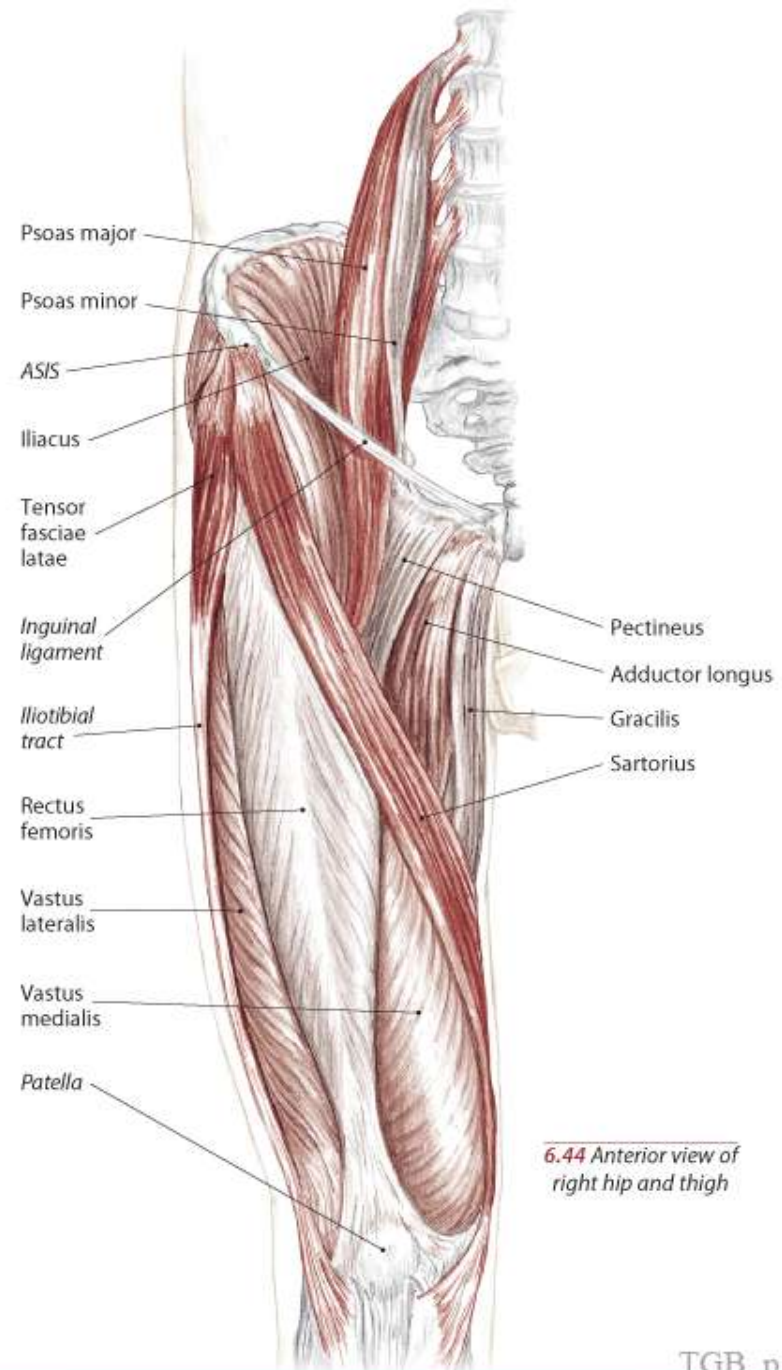
Bony Landmarks

Text



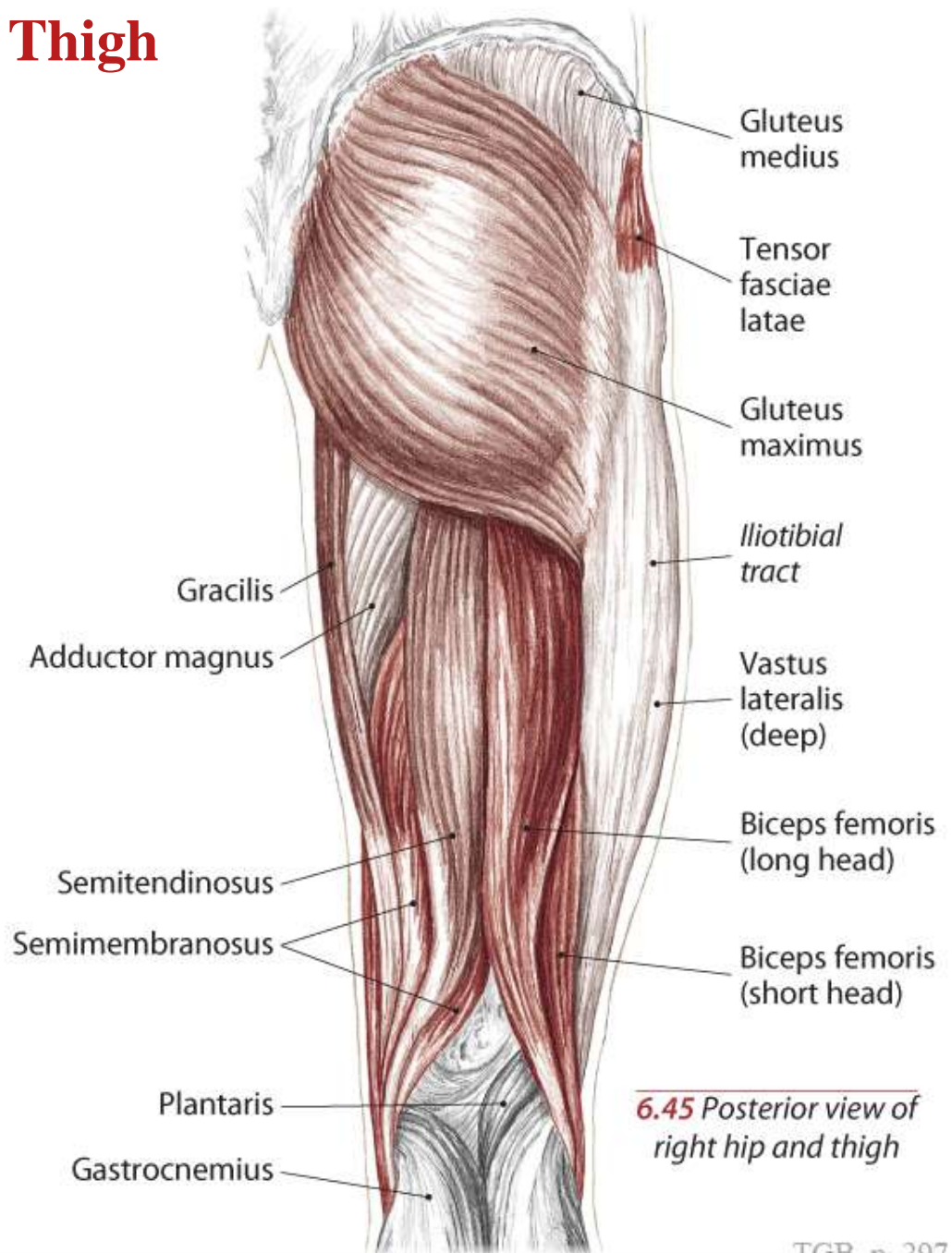
Muscles of the Pelvis and Thigh

Text

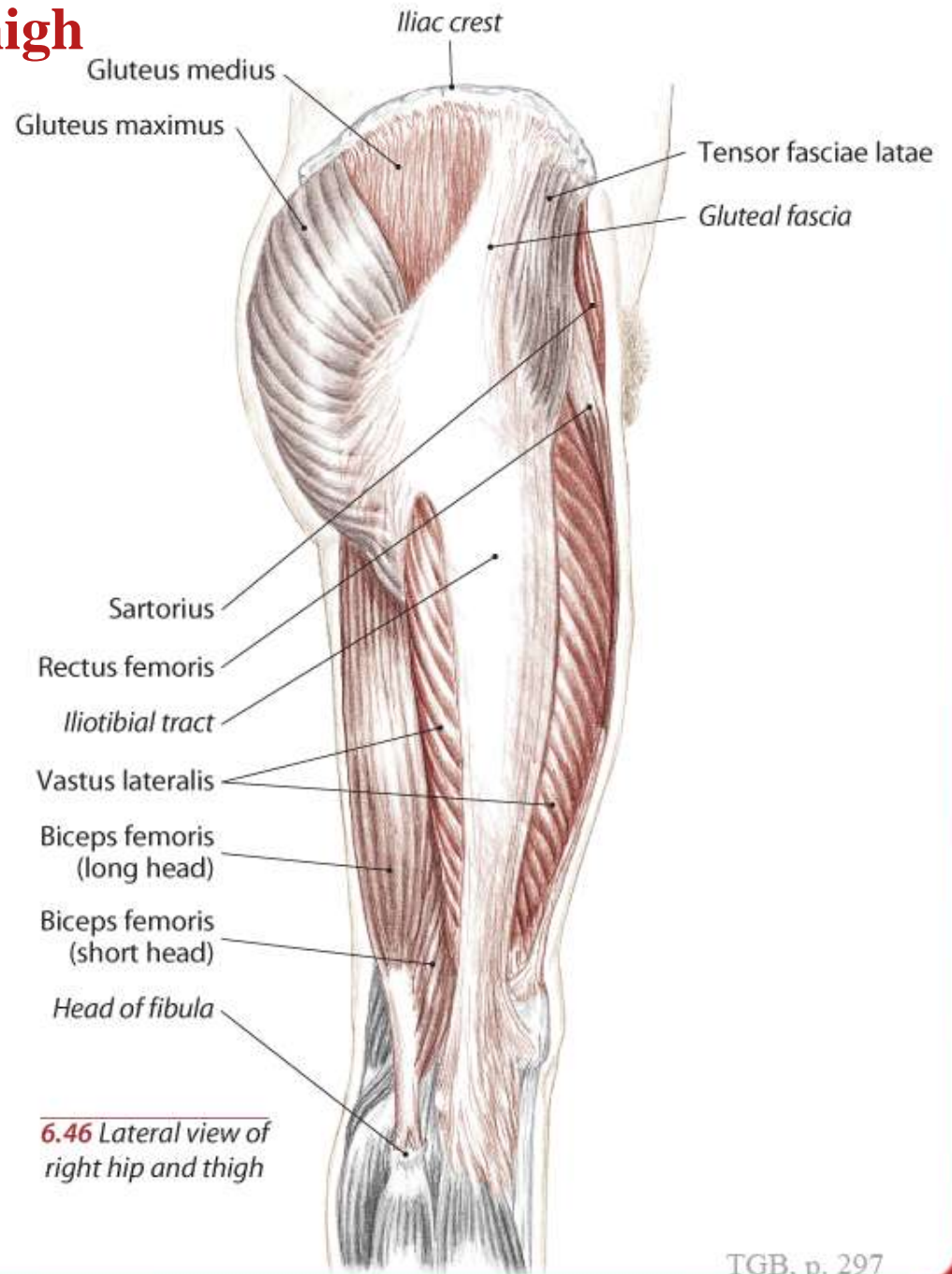


Muscles of the Pelvis and Thigh

Text

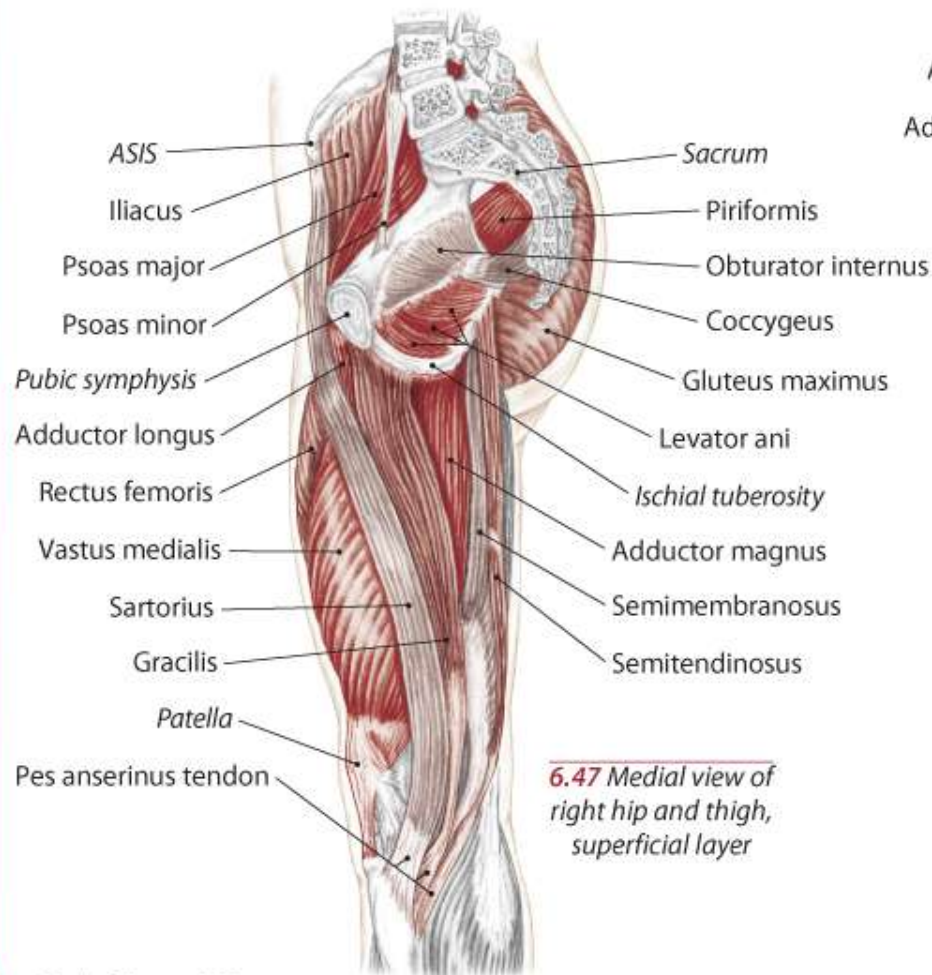


Muscles of the Pelvis and Thigh

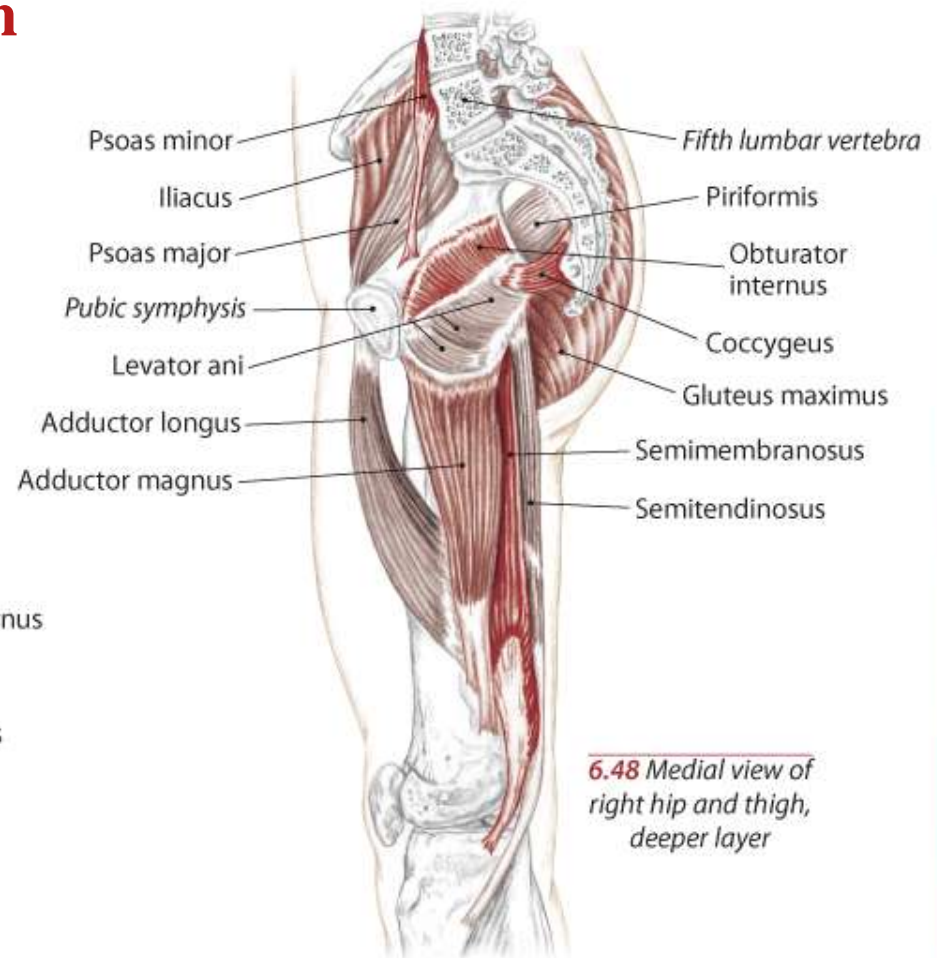


6.46 Lateral view of right hip and thigh

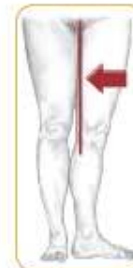Muscles of the Pelvis and Thigh



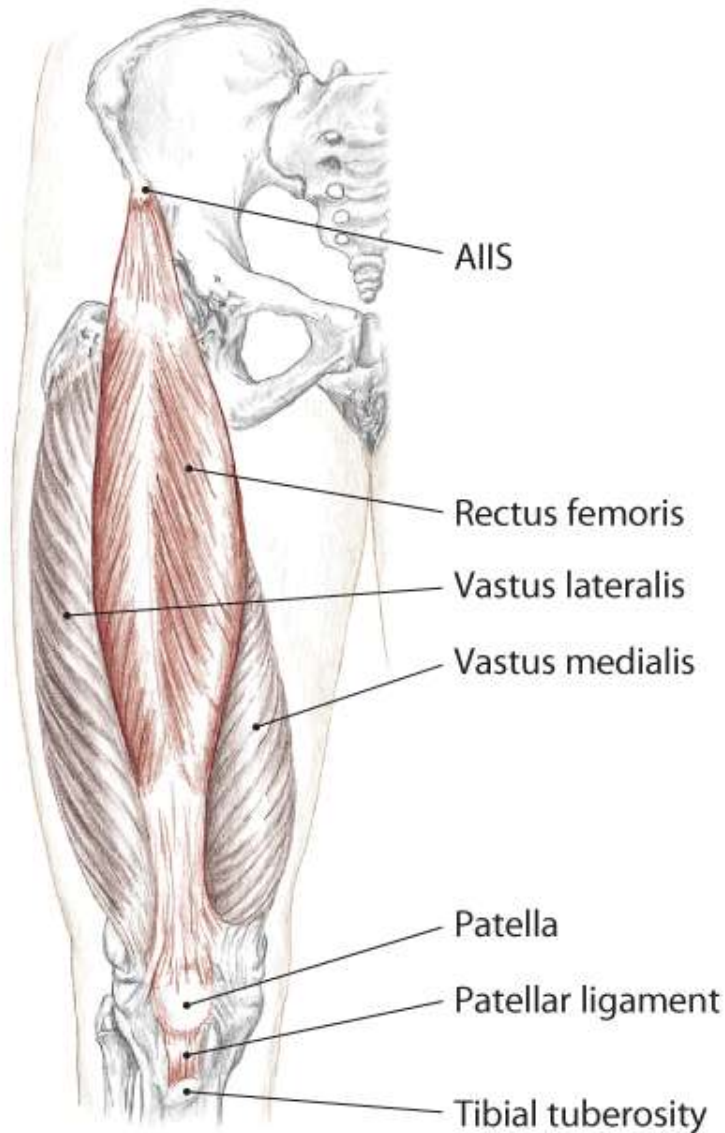
6.47 Medial view of right hip and thigh, superficial layer



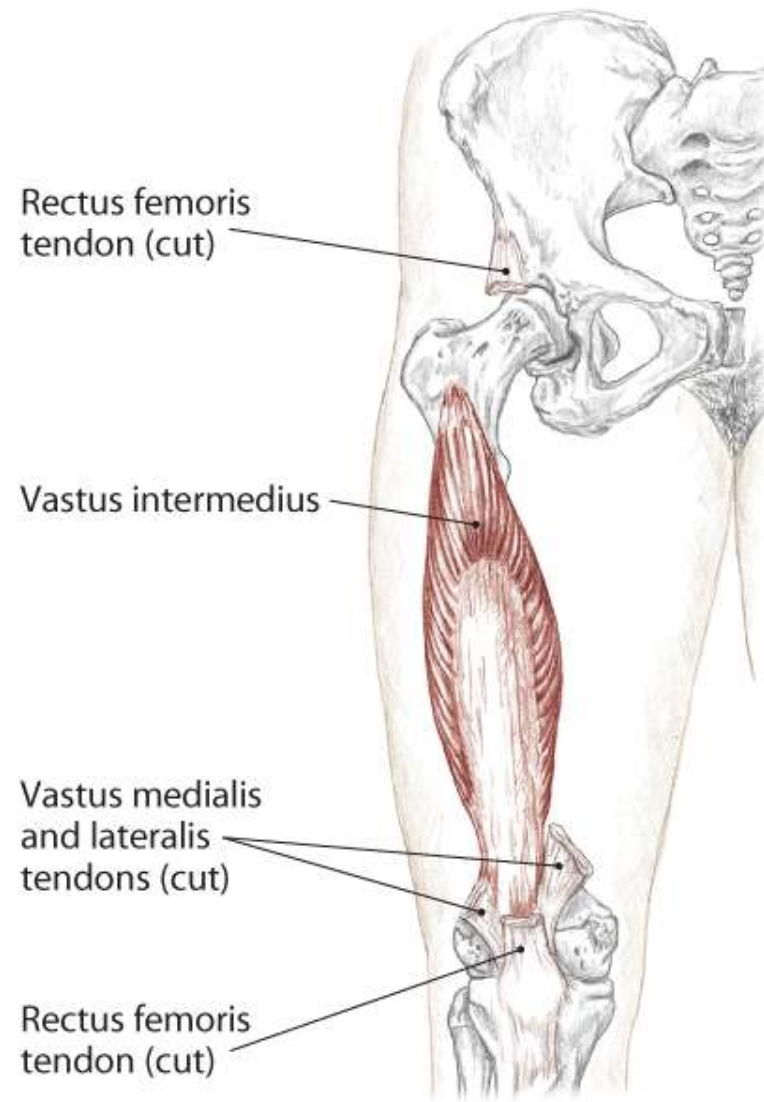
6.48 Medial view of right hip and thigh, deeper layer



Quadriceps Femoris Group



6.55 Anterior view of right hip and thigh



6.56 Anterior view of right hip and thigh

Quadriceps Femoris Group

A All:
Extend the knee (tibiofemoral joint)

Rectus Femoris:
Flex the hip (coxal joint)

O *Rectus Femoris:*
Anterior inferior iliac spine (AIIS)

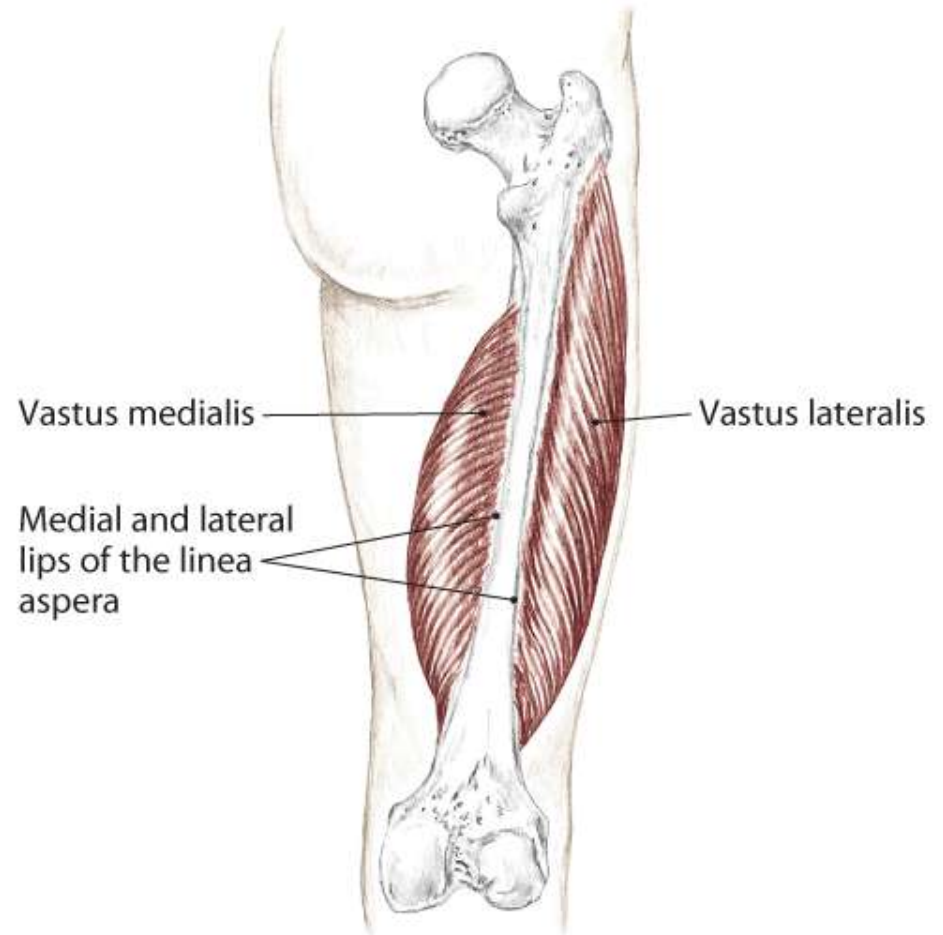
Vastus Medialis:
Medial lip of linea aspera

Vastus Lateralis:
Lateral lip of linea aspera, gluteal tuberosity
and greater trochanter

Vastus Intermedius:
Anterior and lateral shaft of the femur

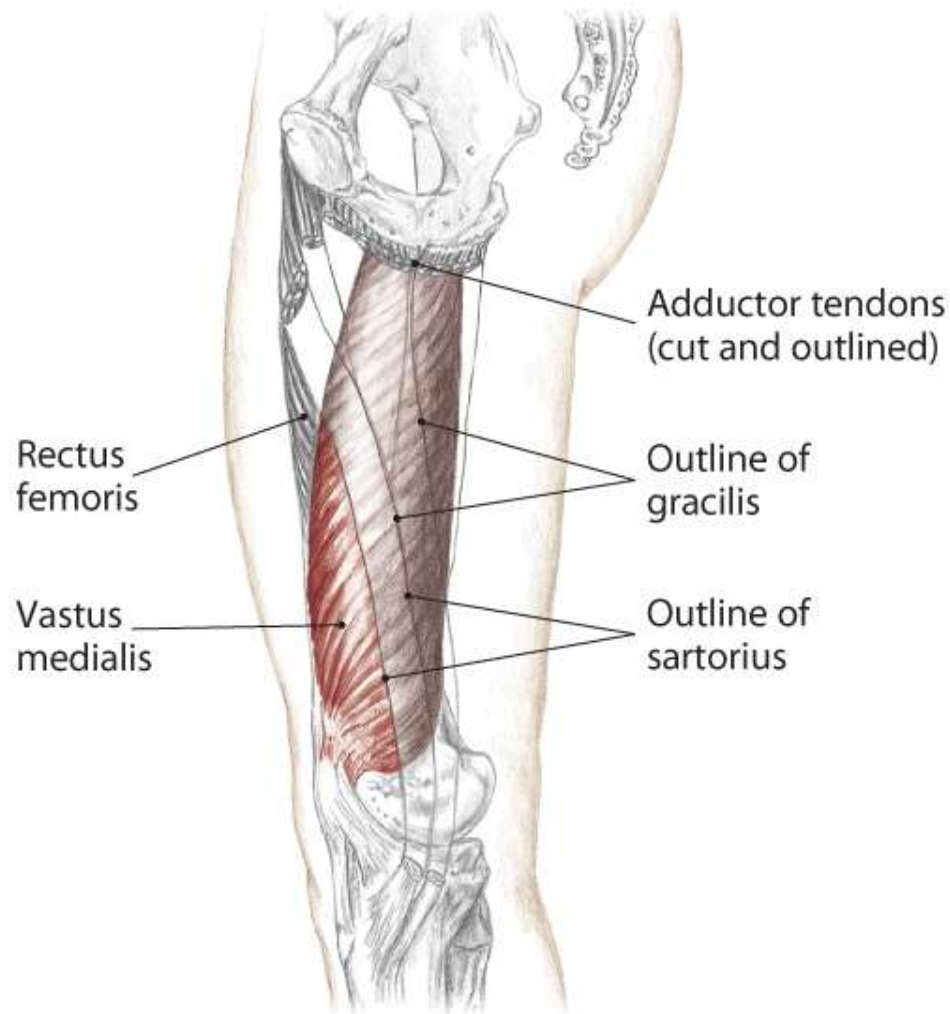
I Tibial tuberosity (via the patella and
patellar ligament)

N Femoral L2, 3, 4

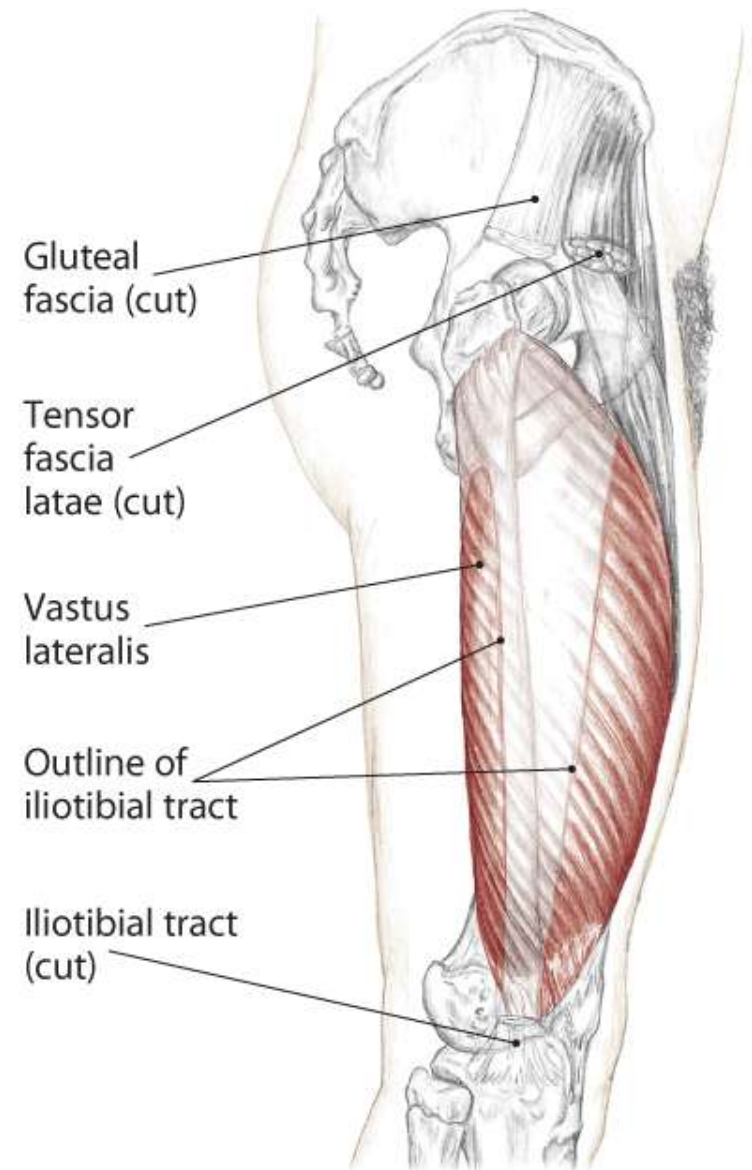


6.59 Posterior view of right femur

Quadriceps Femoris Group

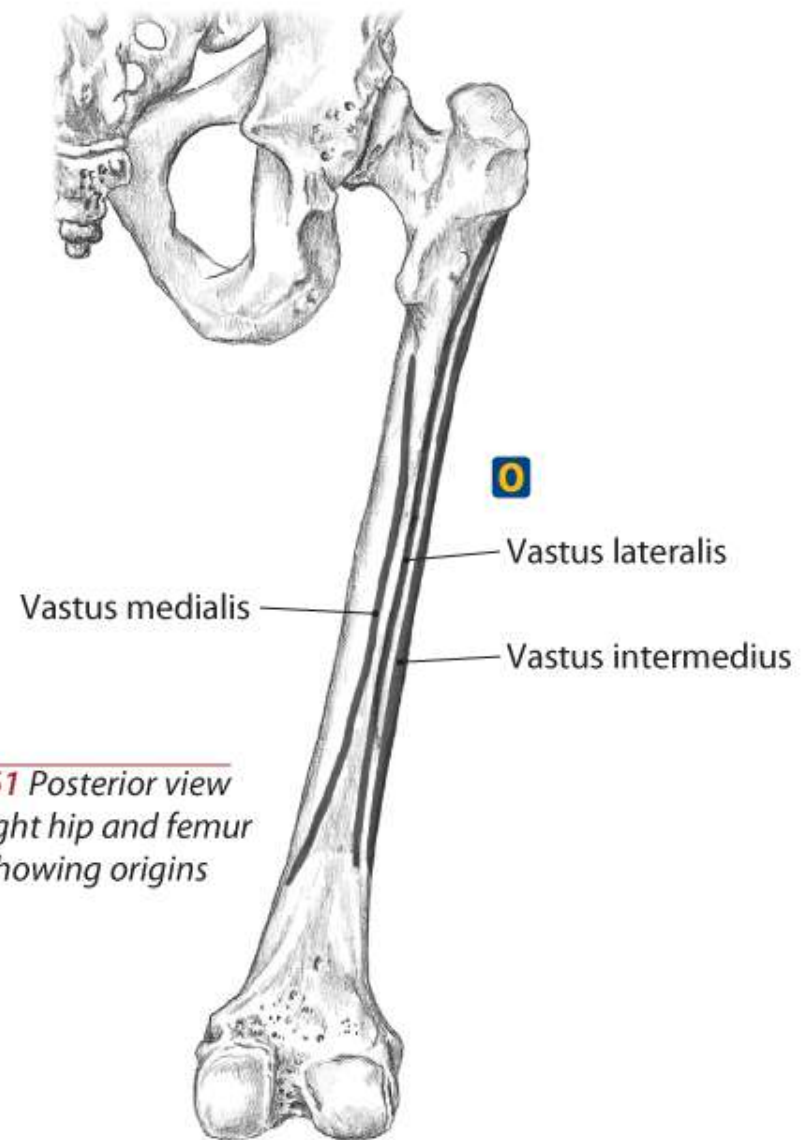
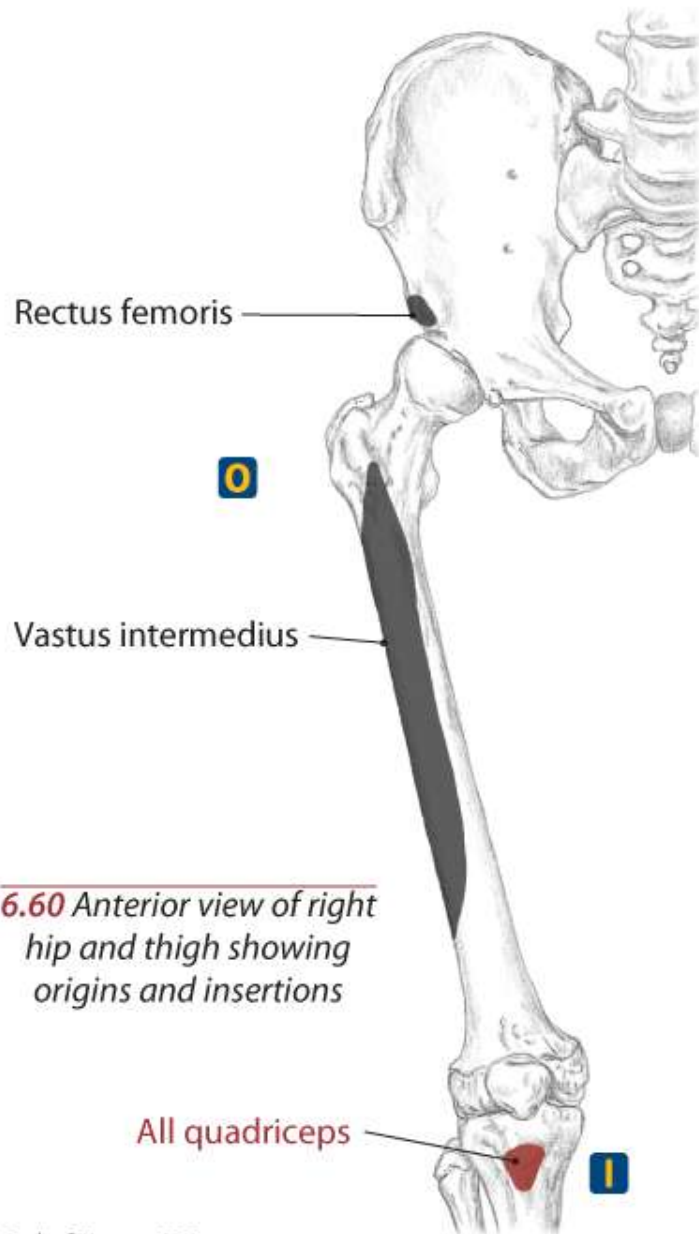


6.57 Medial view of right thigh



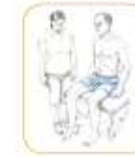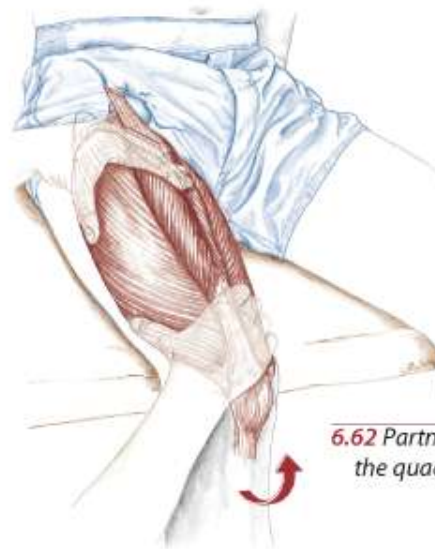6.58 Lateral view of right hip and thigh

Quadriceps Femoris Group



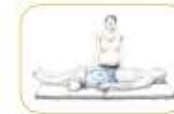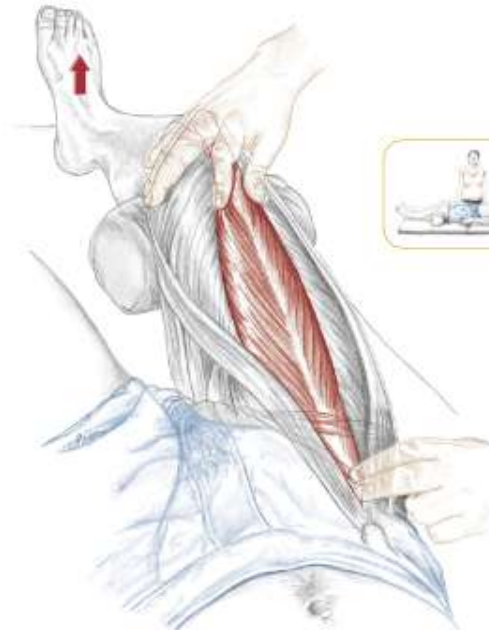
Quadriceps as a Group

Text

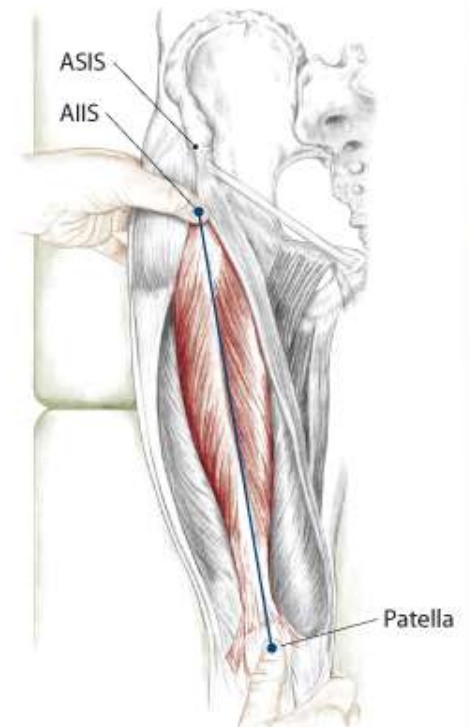


6.62 Partner seated, palpating the quadriceps as a group

Rectus Femoris



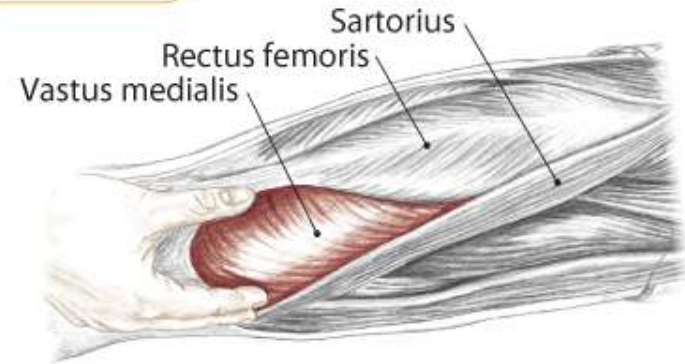
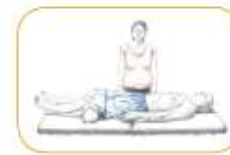6.64 Locating the rectus femoris as your partner flexes his hip and holds his foot off the table



6.63 Anterior view, drawing a line between the AIIS and patella to isolate the rectus femoris

Vastus Medialis

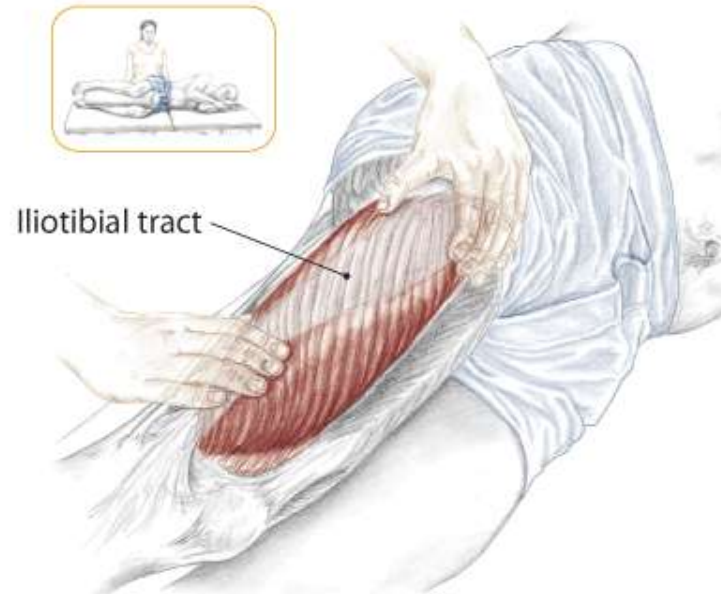
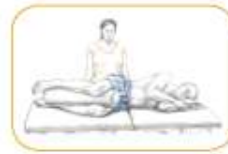Text



6.65 Partner supine, anterior/medial view of right thigh

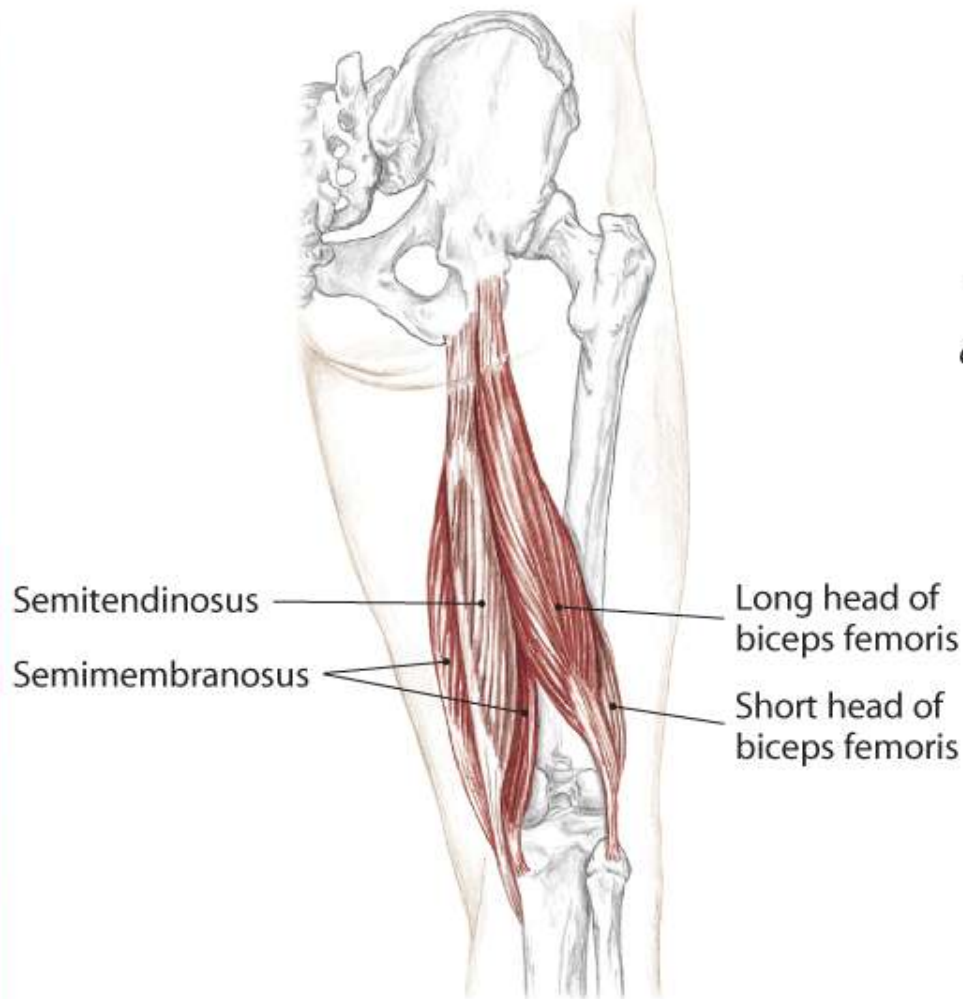
Vastus Lateralis

Text

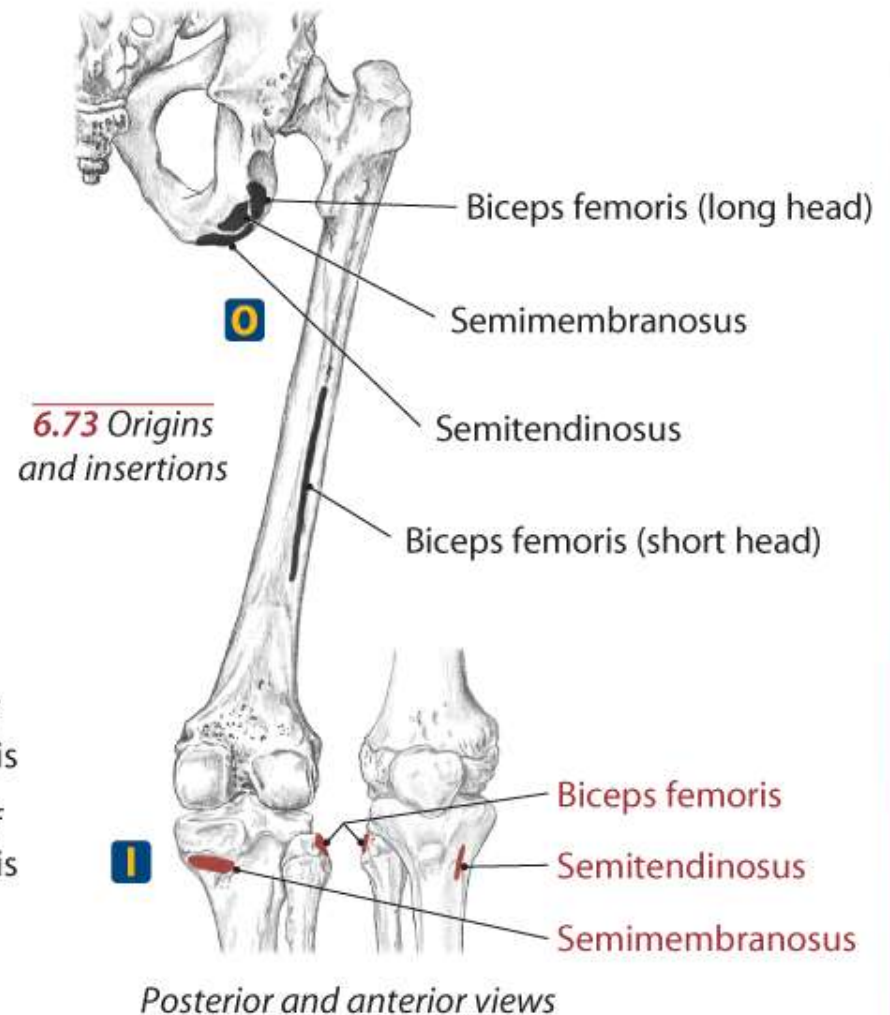


6.66 Partner side lying, palpating the vastus lateralis deep to the iliotibial tract

Hamstrings



6.68 Posterior view of right thigh showing superficial hamstrings



Hamstrings

Biceps Femoris

A Flex the knee (tibiofemoral joint)

Laterally rotate the flexed knee (T/F joint)

Long head: **Extend** the hip (coxal joint)

Long head: Assist to **laterally rotate** the hip (coxal joint)

Tilt the pelvis posteriorly

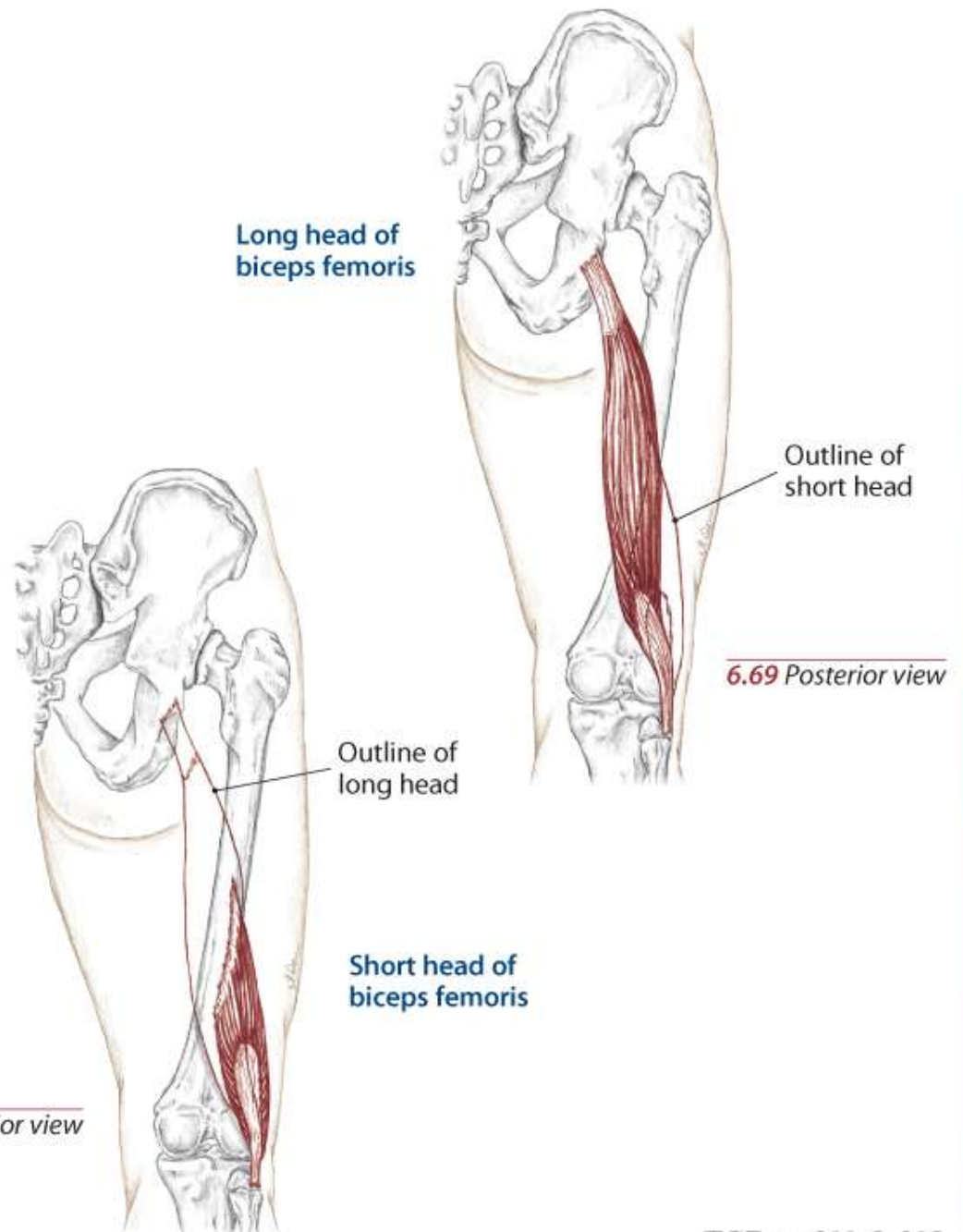
O **Long head:** Ischial tuberosity

Short head: Lateral lip of linea aspera

I Head of the fibula

N **Long head:** Sciatic (tibial branch) L5, S1, 2, 3

Short head: Sciatic (peroneal branch) L5, S1, 2



Hamstrings

Semitendinosus

A **Flex** the knee (tibiofemoral joint)

Medially rotate the flexed knee (T/F joint)

Extend the hip (coxal joint)

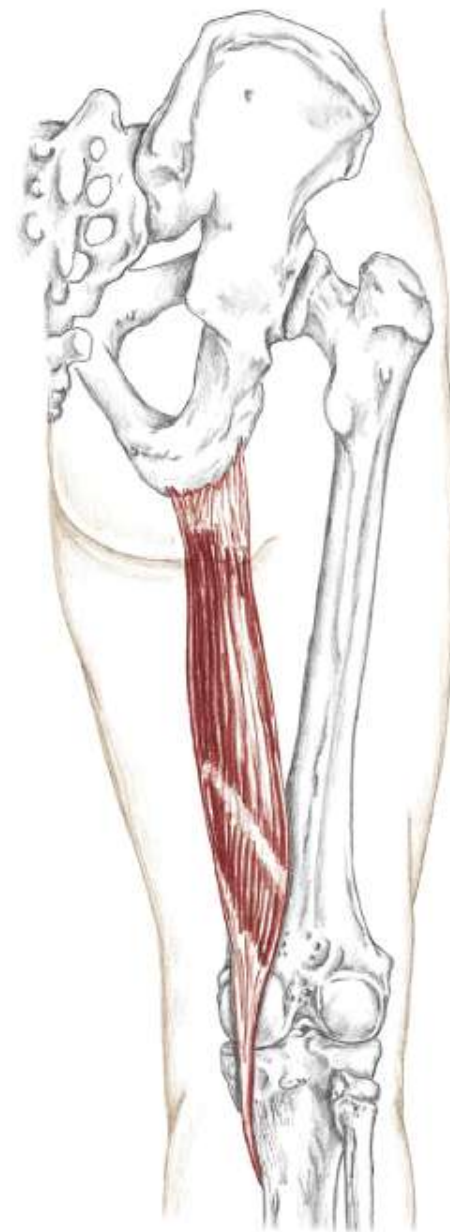Assist to **medially rotate** the hip (coxal joint)

Tilt the pelvis posteriorly

O Ischial tuberosity

I Proximal, medial shaft of the tibia
at pes anserinus tendon

N Sciatic (tibial branch) L4, 5, S1, 2



6.71 *Posterior view*

Hamstrings

Semimembranosus

A **Flex** the knee (tibiofemoral joint)

Medially rotate the flexed knee (T/F joint)

Extend the hip (coxal joint)

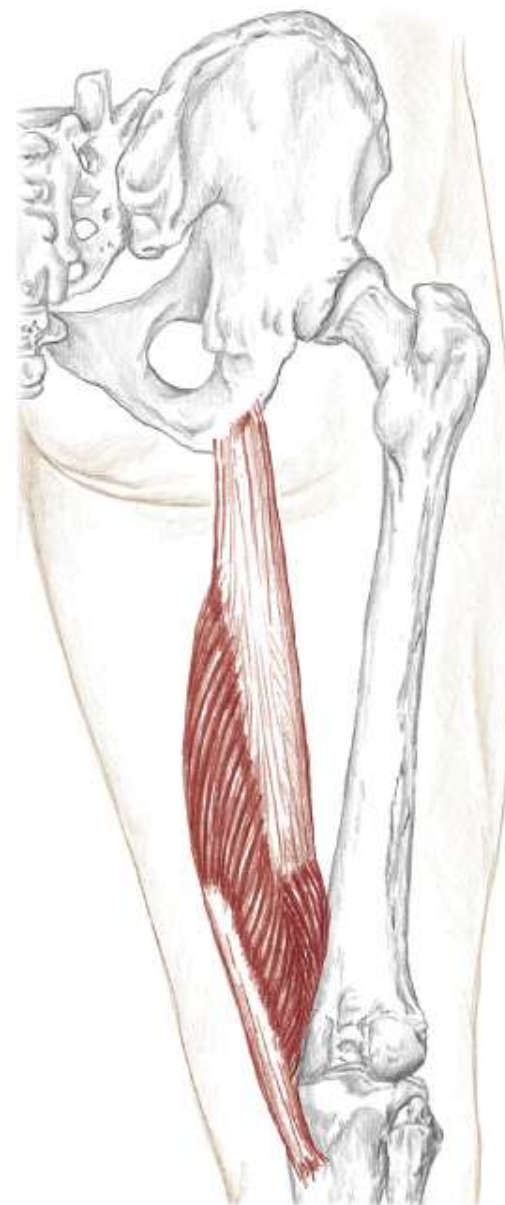
Assist to **medially rotate** the hip (coxal joint)

Tilt the pelvis posteriorly

O Ischial tuberosity

I Posterior aspect of medial condyle of tibia

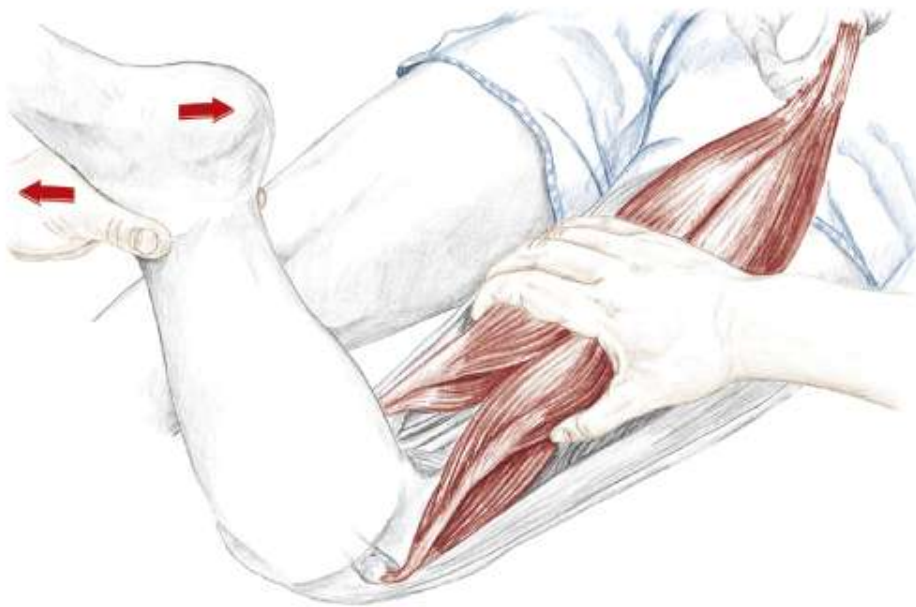
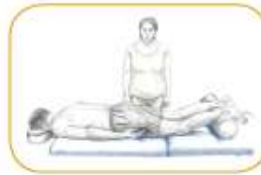N Sciatic (tibial branch) L4, **5**, S1, 2



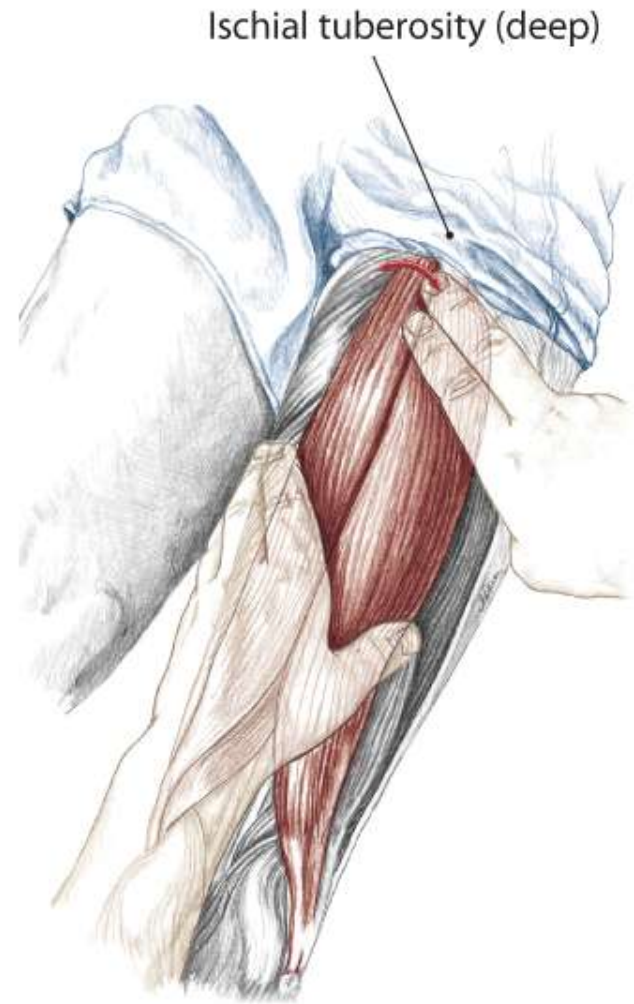
6.72 *Posterior view*

Hamstrings as a Group

Text



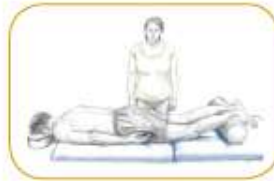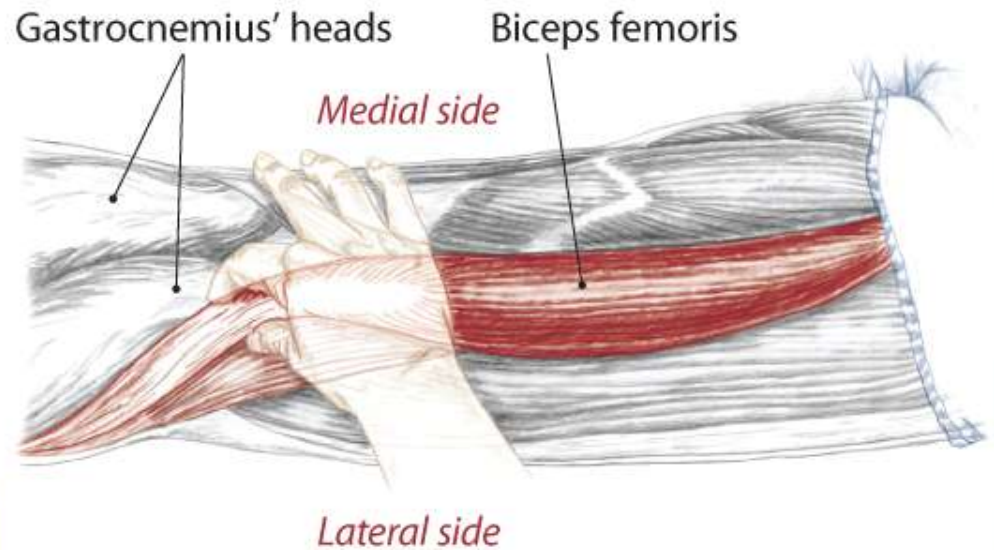
6.74 Partner prone, grasping the hamstrings group



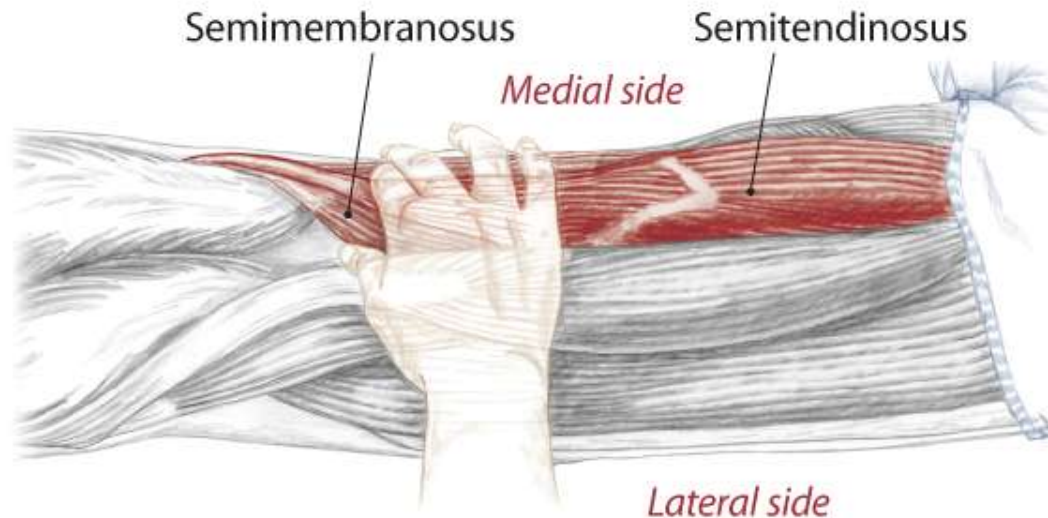
6.75 Partner prone, isolating the hamstrings tendon at the ischial tuberosity

Individual Bellies and Distal Tendons

Text



6.77 Partner prone, posterior/lateral view of right knee

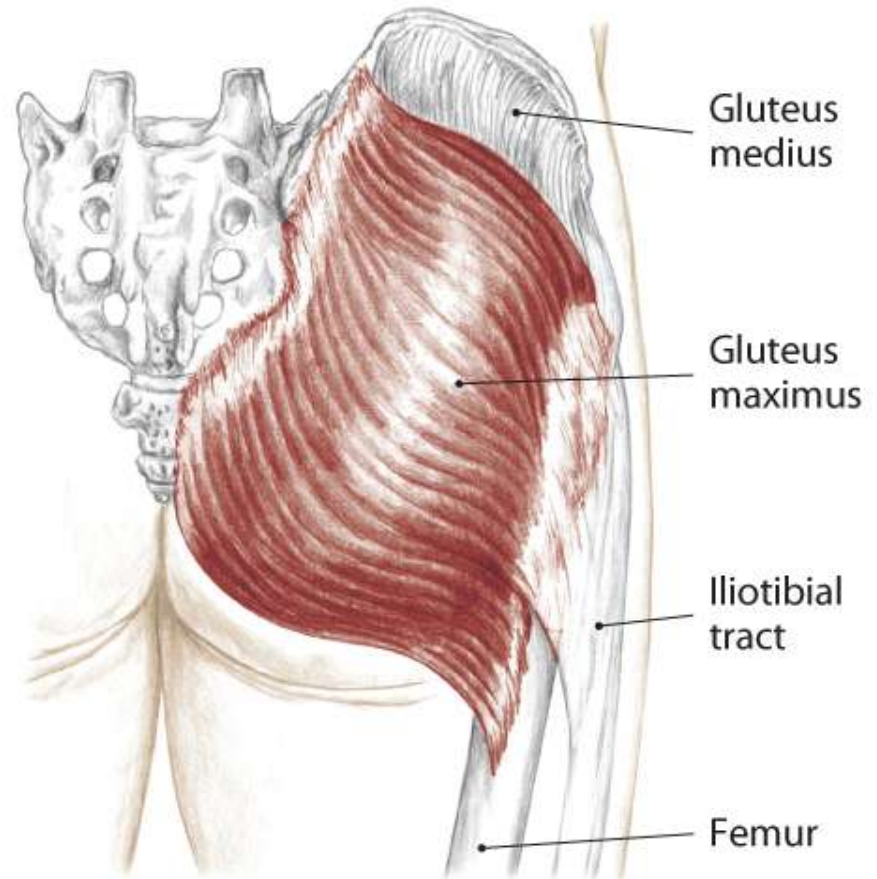


6.78 Partner prone, posterior/lateral view of right knee

Gluteals

Gluteus Maximus

- A** All fibers:
 - Extend** the hip (coxal joint)
 - Laterally rotate** the hip (coxal joint)
 - Abduct** the hip (coxal joint)
- Lower fibers:
 - Adduct** the hip (coxal joint)
- O** Coccyx, edge of sacrum, posterior iliac crest, sacrotuberous and sacroiliac ligaments
- I** Iliotibial tract (upper fibers) and gluteal tuberosity (lower fibers)
- N** Inferior gluteal L5, S1, 2



6.79 Posterior view of right buttock

Gluteals

Gluteus Medius

A All fibers:
Abduct the hip (coxal joint)

Anterior fibers:
Flex the hip (coxal joint)

Medially rotate the hip (coxal joint)

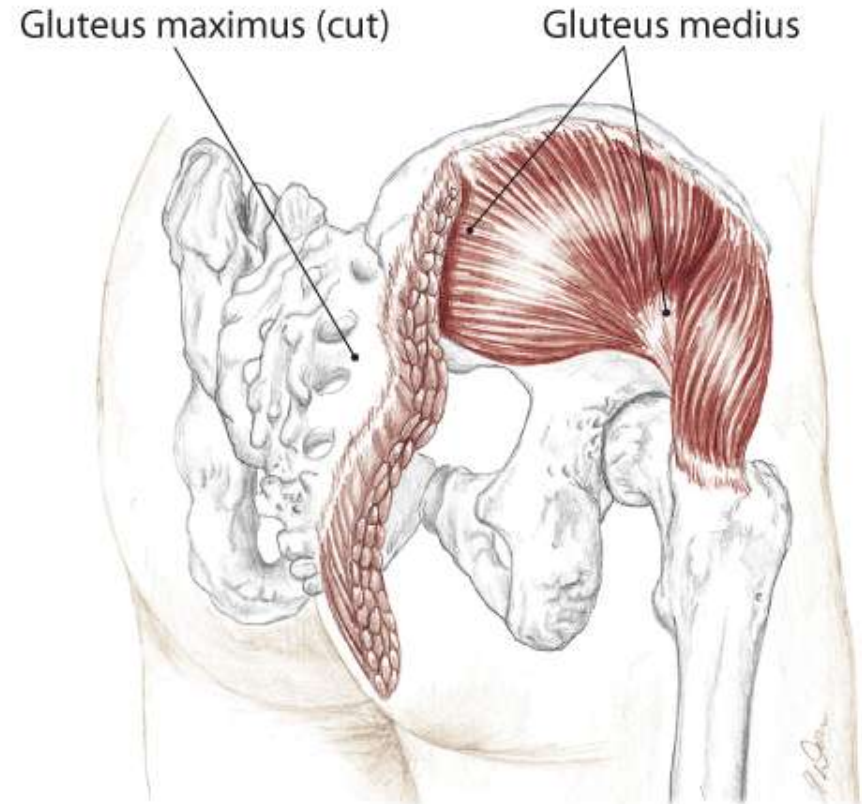
Posterior fibers:
Extend the hip (coxal joint)

Laterally rotate the hip (coxal joint)

O Gluteal surface of ilium, between posterior and anterior gluteal lines, just below the iliac crest

I Lateral aspect of greater trochanter

N Superior gluteal L4, 5, S1

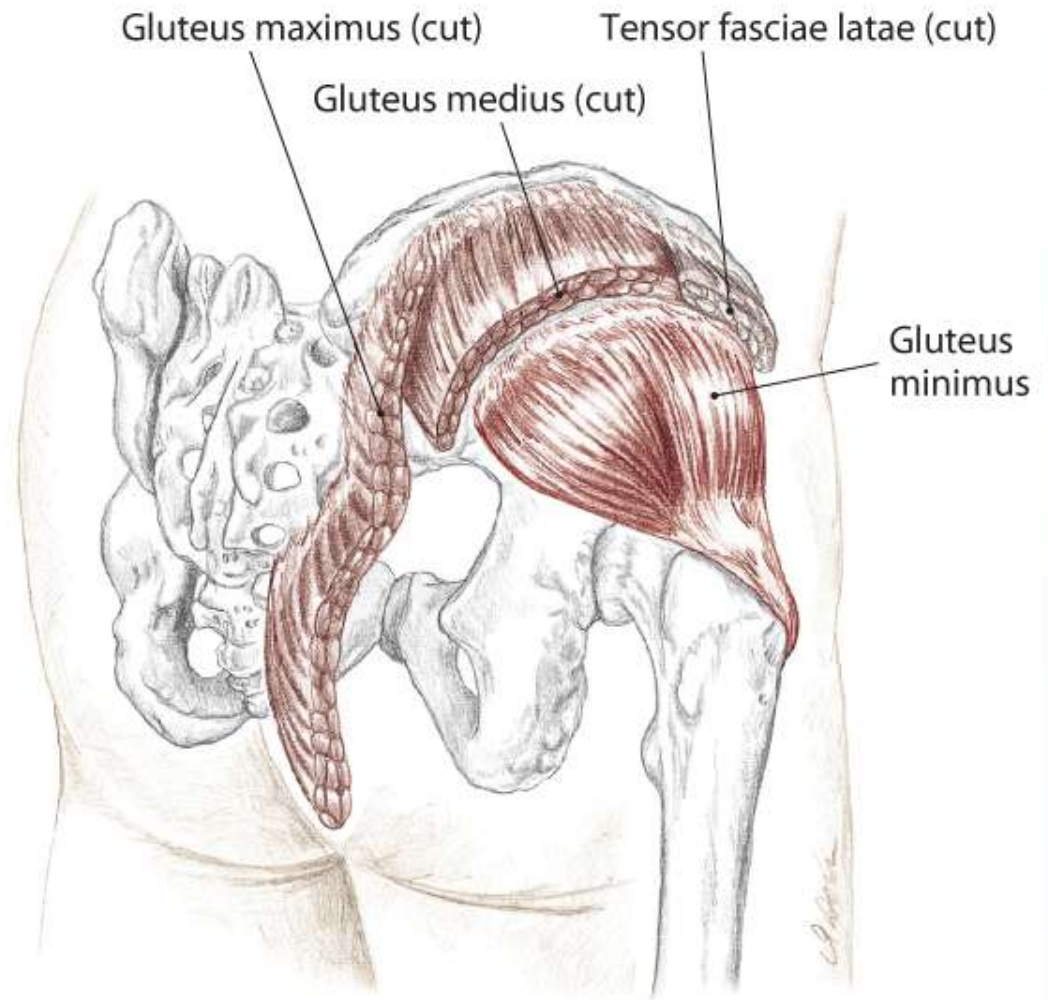


6.80 Posterior/lateral view of right buttock

Gluteals

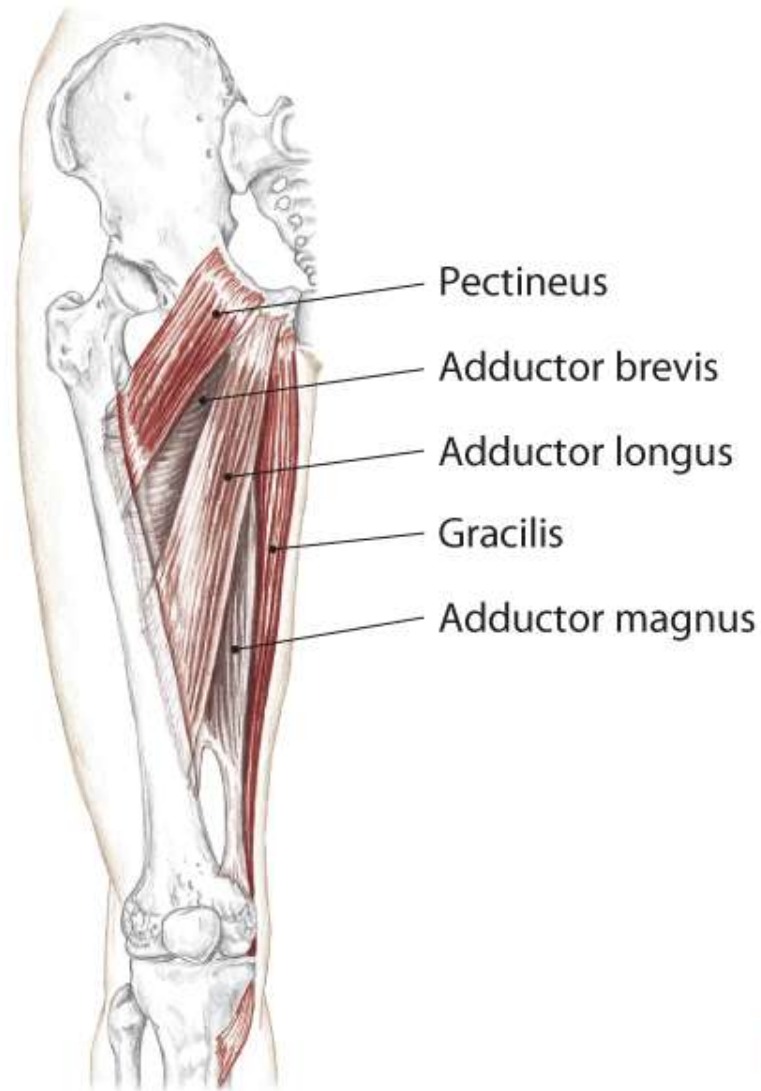Gluteus Minimus

- A** **Abduct** the hip (coxal joint)
Medially rotate the hip (coxal joint)
Flex the hip (coxal joint)
- O** Gluteal surface of the ilium between the anterior and inferior gluteal lines
- I** Anterior aspect of greater trochanter
- N** Superior gluteal L4, 5, S1

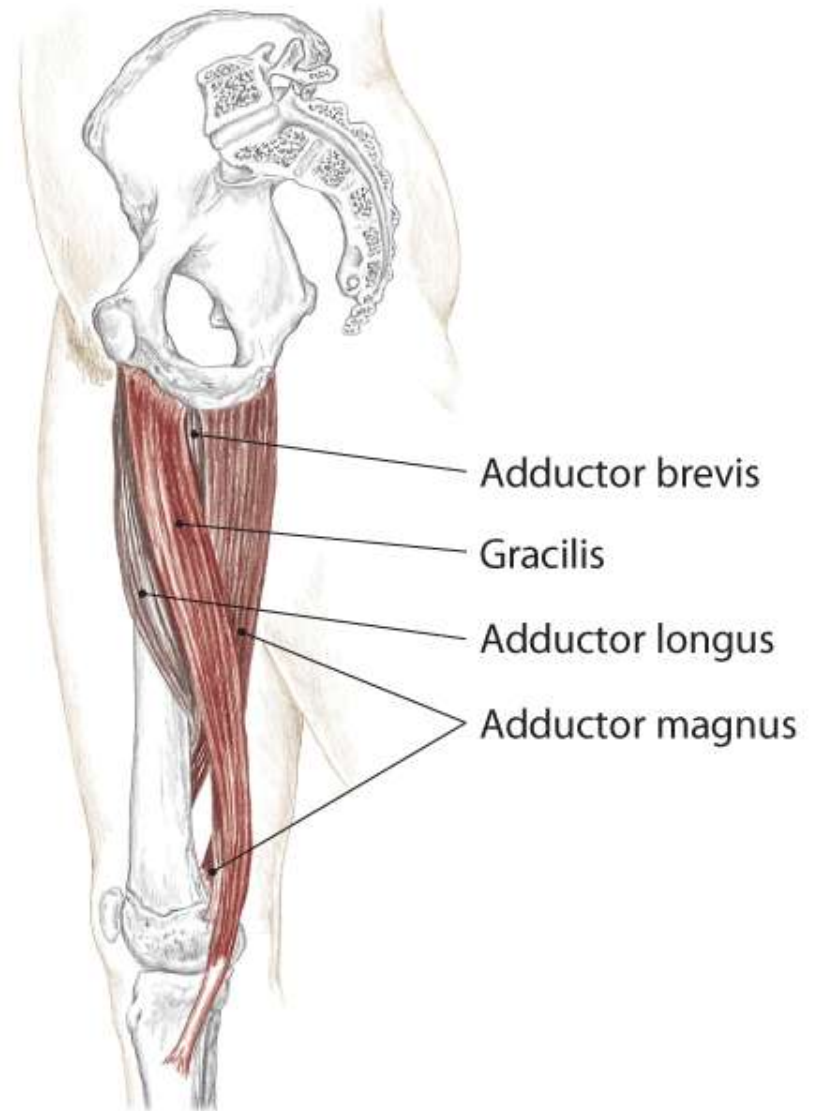


6.81 Posterior/lateral view of right buttock

Adductor Group



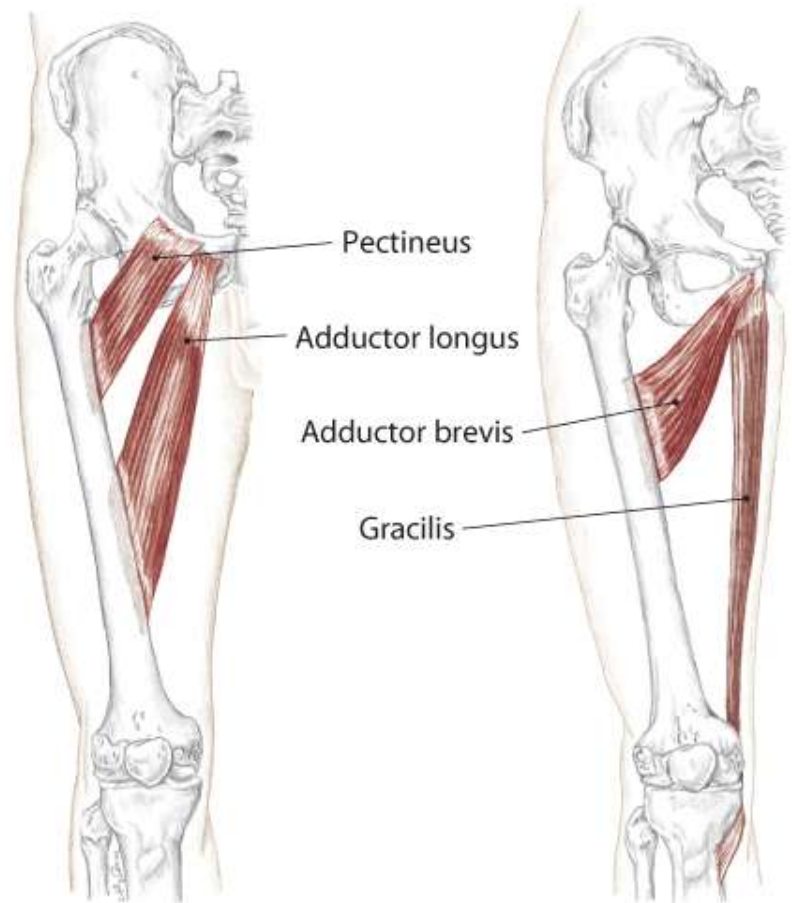
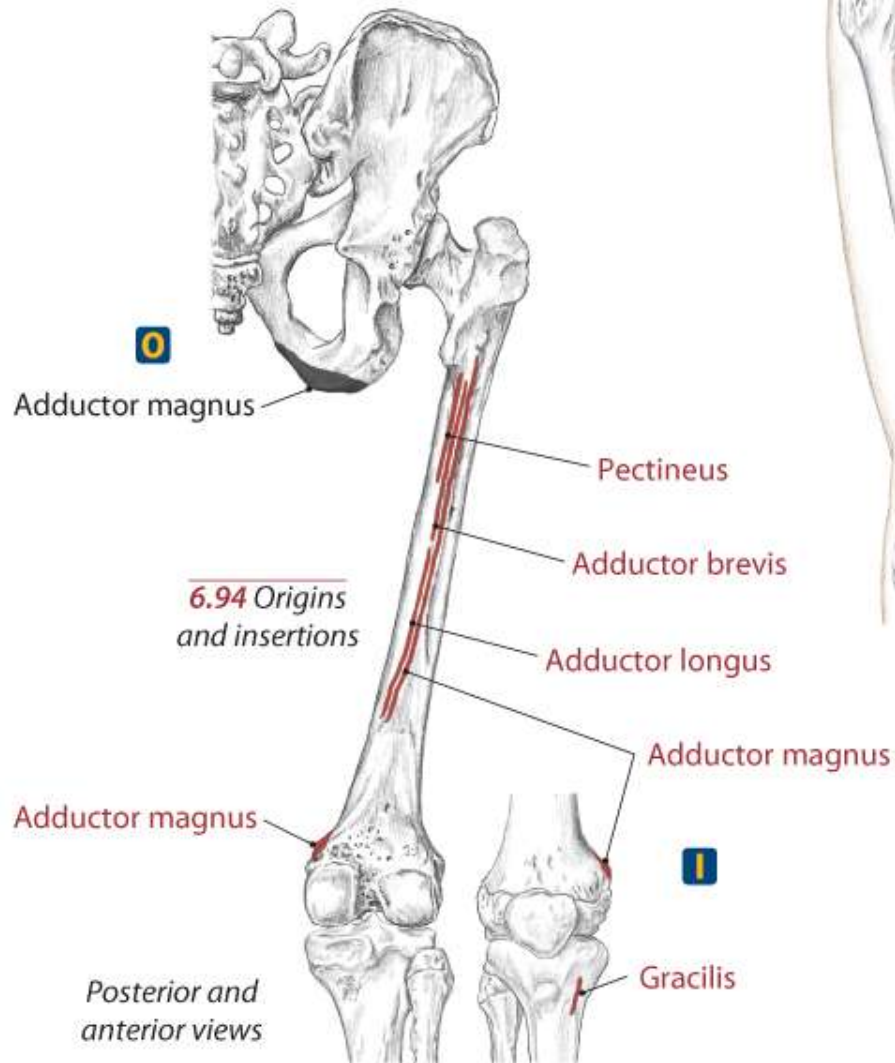
6.88 Anterior view of right hip and thigh



6.89 Medial view of right hip and thigh

Adductor Group

Text



6.90, 6.91 Anterior views of right hip and thigh

Adductor Group

A All:
Adduct the hip (coxal joint)

Medially rotate the hip (coxal joint)

All, except *Gracilis*:
Assist to **flex** the hip (coxal joint)

Gracilis:
Flex the knee (tibiofemoral joint)

Medially rotate the flexed knee (T/F joint)

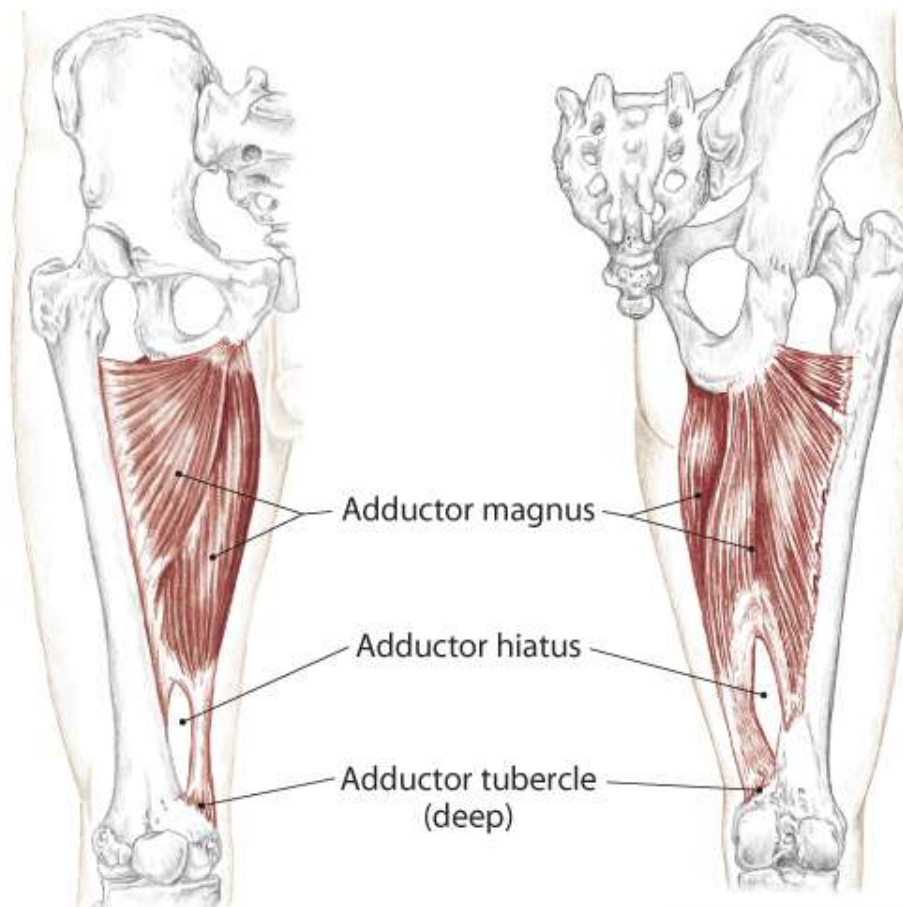
Posterior fibers of *Adductor Magnus*:
Extend the hip (coxal joint)

Adductor Magnus

O Inferior ramus of the pubis, ramus of ischium and ischial tuberosity

I Medial lip of linea aspera and adductor tubercle

N Obturator L2, 3, 4 and Sciatic L4, 5, S1



6.92 Anterior view of right hip and thigh

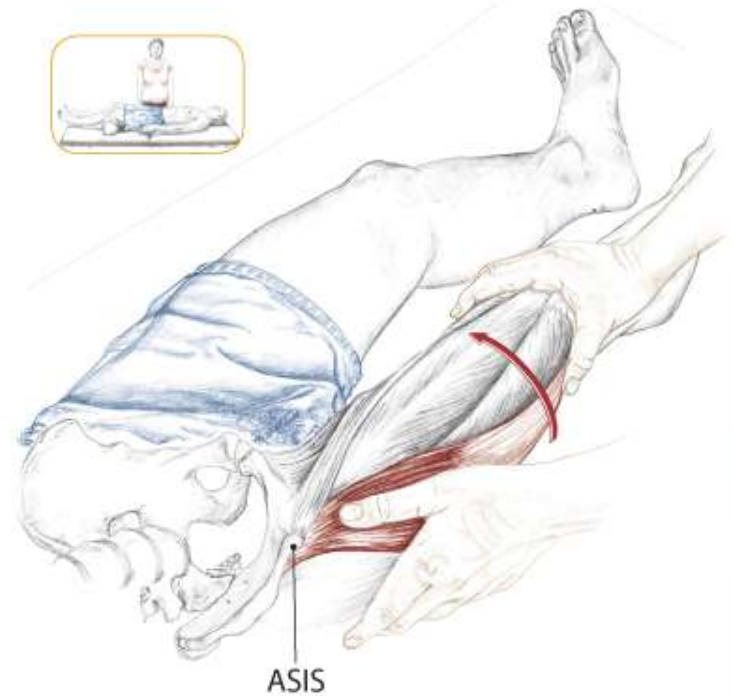
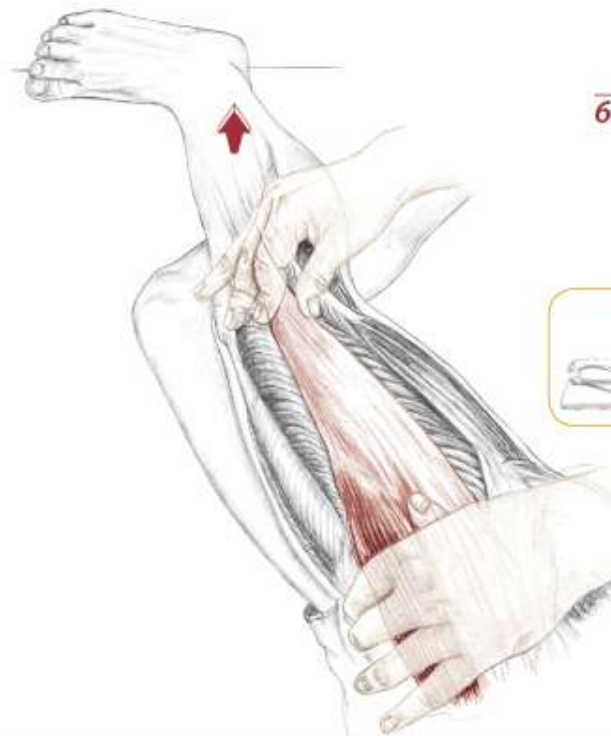6.93 Posterior view of right hip and thigh

Tensor Fasciae Latae

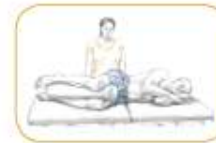Text

Distal End of the Iliotibial Tract

Text



6.104 Partner supine, feeling the TFL contract as your partner medially rotates his hip

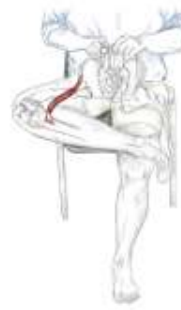

6.105 Partner side lying, palpating the distal end of the iliotibial tract and TFL as your partner abducts his hip

Sartorius

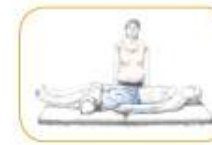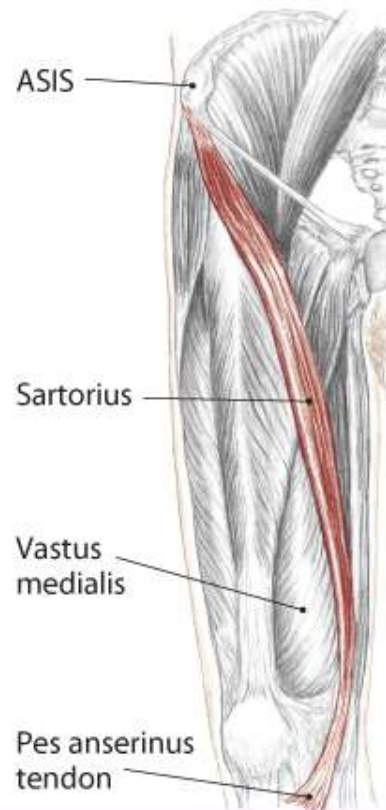
- A** Flex the hip (coxal joint)
- Laterally rotate** the hip (coxal joint)
- Abduct** the hip (coxal joint)
- Flex** the knee (tibiofemoral joint)
- Medially rotate** the flexed knee (T/F joint)

- O** Anterior superior iliac spine (ASIS)
- I** Proximal, medial shaft of the tibia at pes anserinus tendon
- N** Femoral L2, 3, (4)

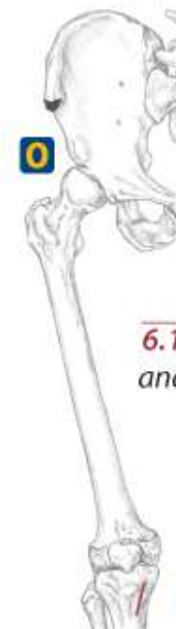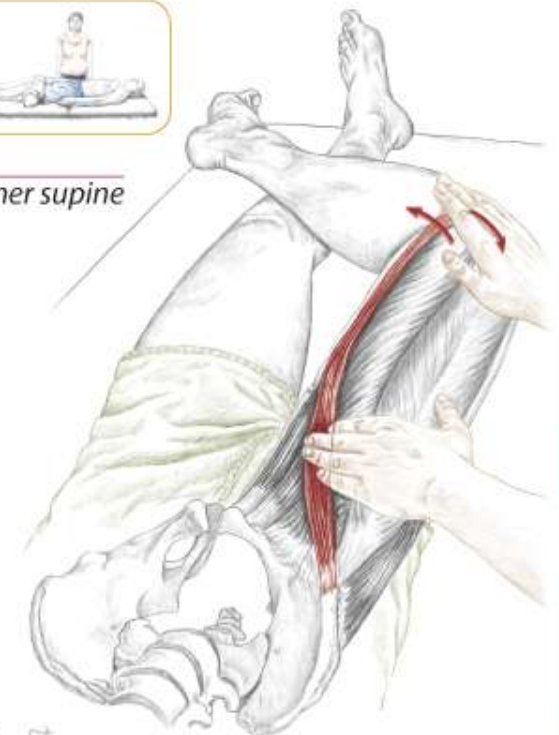


6.106

6.107 Anterior/medial view of right hip and thigh



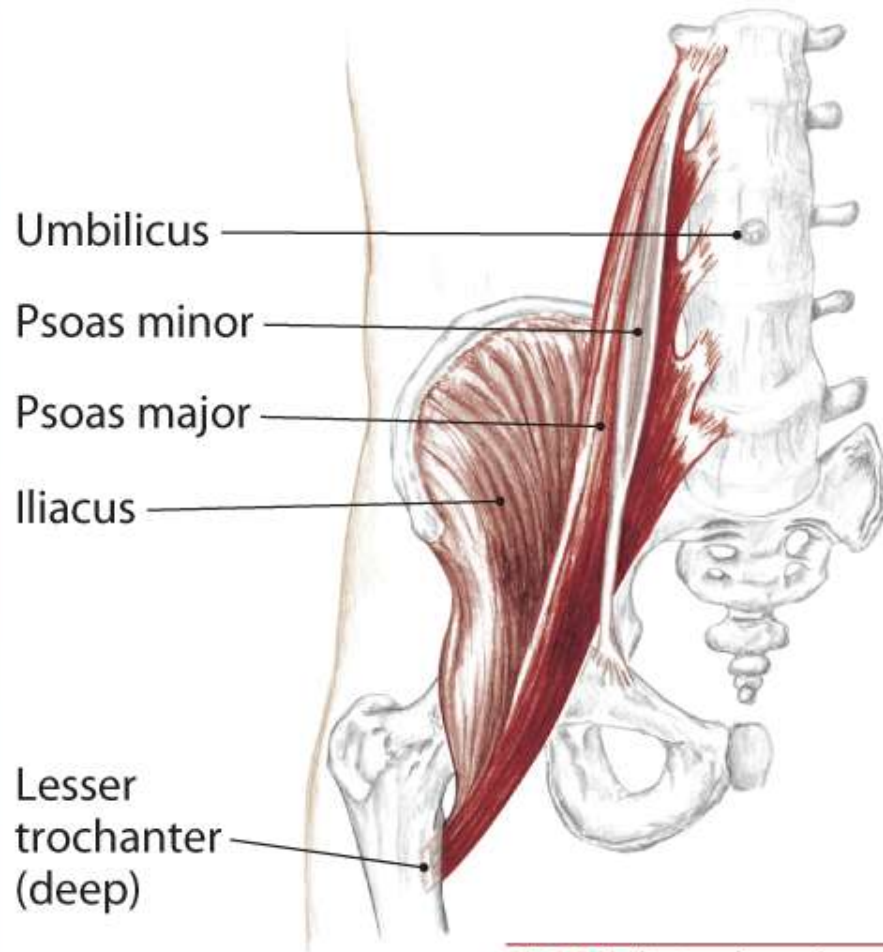
6.109 Partner supine



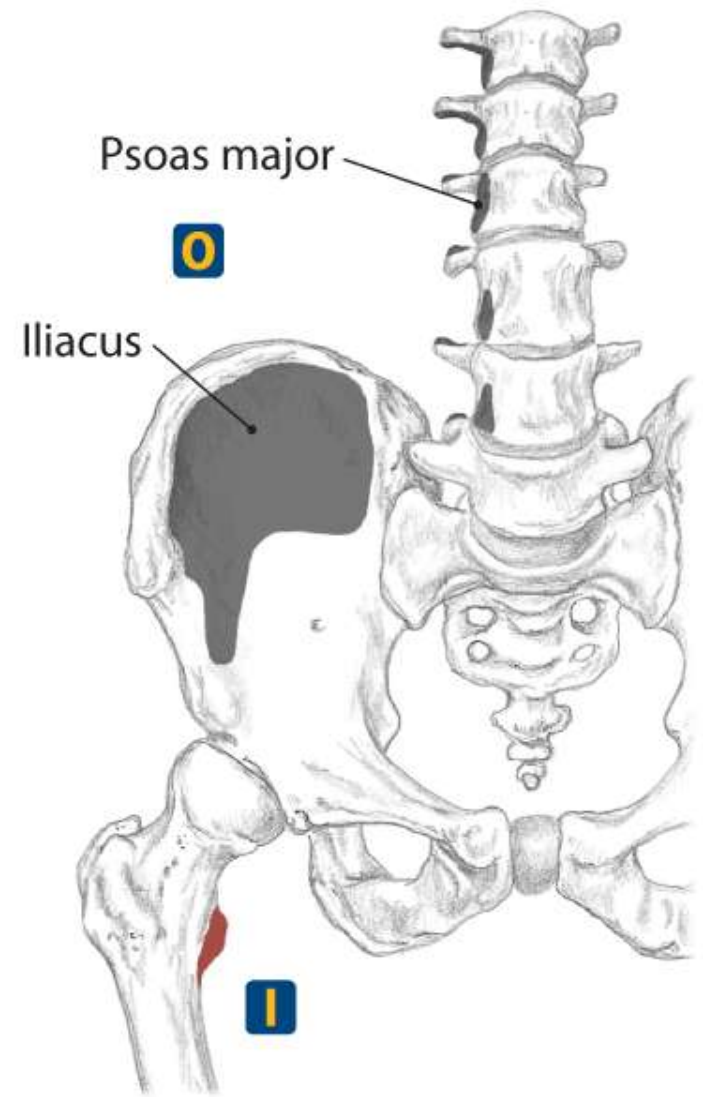
6.108 Origin and insertion

Iliopsoas

Psoas Major
Iliacus



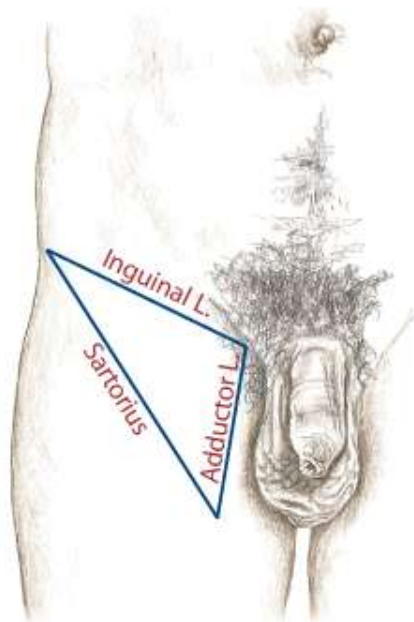
6.126 Anterior view of spine and right hip



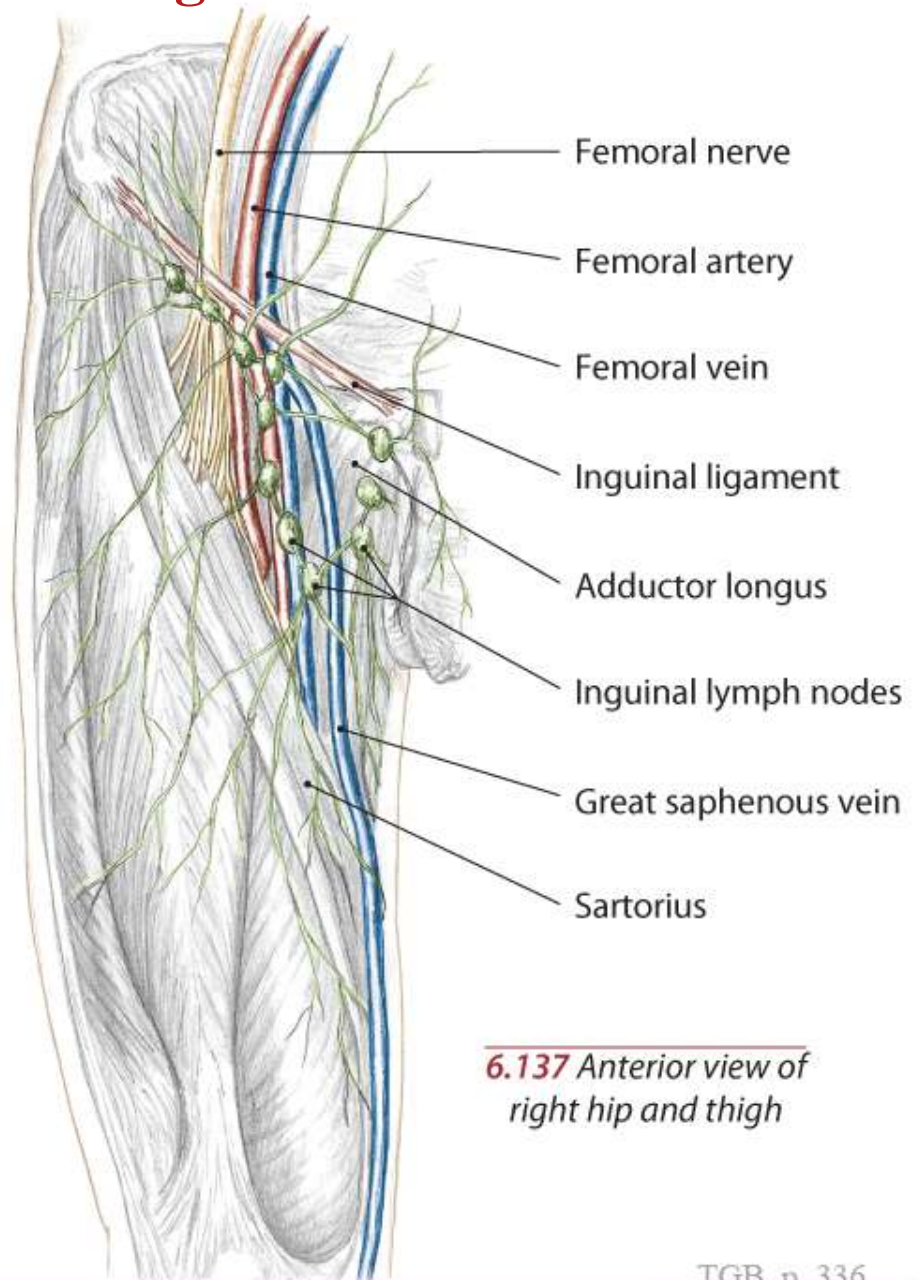
6.129 Anterior view of spine and right hip showing origins and insertions

Other Structures of the Pelvis and Thigh

Text



6.136 The three borders of the femoral triangle



6.137 Anterior view of right hip and thigh

The End